

Diagnostic Accuracy Of Mr Spectroscopy For The Detection Of Supratentorial Neoplastic Space-Occupying Lesions Of The Brain By Taking Histopathology As The Gold Standard At Tertiary Care Hospital, Karachi

Dr. Mehak ¹, Dr. Naureen Farhan ², Dr. Amber Shams³, Dr. Bhavesh Sagar⁴, Dr. Faryal Zafar⁵

¹MBBS, FCPS (Radiology), Resident, Diagnostic Radiology, Dr. Ziauddin University Hospital

²MBBS, FCPS, EDiR (Radiology), Assistant Professor, Diagnostic Radiology, Dr. Ziauddin University Hospital

³ MBBS, MRCPI (Part II –W Gynae & Obs RCPI ,IRELAND

Email ID : Drambershams@gmail.com

⁴. MBBS, FCPS (Radiology), Resident, Diagnostic Radiology, Dr. Ziauddin University Hospital

⁵. MBBS (University of Health Sciences), MPhil (Histopathology) (NUMS University, Rawalpindi)

Corresponding author

Dr. Amber Shams,

MBBS, MRCPI (Part II –W Gynae & Obs RCPI ,IRELAND

Email ID : Drambershams@gmail.com

Cite this paper as: Dr. Mehak , Dr. Naureen Farhan , Dr. Amber Shams, Dr. Bhavesh Sagar, Dr. Faryal Zafar (2025) Diagnostic Accuracy Of Mr Spectroscopy For The Detection Of Supratentorial Neoplastic Space-Occupying Lesions Of The Brain By Taking Histopathology As The Gold Standard At Tertiary Care Hospital, Karachi..Journal of Neonatal Surgery, 14, (32s) 10255-10261

ABSTRACT

Objective: To determine the diagnostic accuracy of MR spectroscopy for the detection of supratentorial neoplastic space-occupying lesions of the brain by taking histopathology as the gold standard at Tertiary Care Hospital, in Karachi.

Design: Cross-sectional study

Place and Duration of Study: This study was conducted from 11th May 2024 to 10th Nov 2024 at the Department of Radiology, Ziauddin Hospital

Methodology: The diagnosis of benign and malignant intracranial lesions based solely on imaging methods remains a challenging problem. Patients aged 20 to 70 years underwent MR spectroscopy for the detection of supratentorial neoplastic space-occupying lesions of the brain. A histopathological assessment of biopsy specimens was performed to establish the final diagnosis. Diagnostic performance measures, including sensitivity, specificity, positive predictive value (PPV), negative predictive value (NPV), and overall diagnostic accuracy of MR spectroscopy, were calculated using histopathology as the gold standard.

Results: The average age of the patients was 40.68±12.05 years (Range: 21-69). There were more males (61.24%) than females (38.76%). The prevalence of neoplastic space-occupying lesions was 75.97% [95% CI: 68.6%–83.3%]. The sensitivity, specificity, PPV, NPV, and diagnostic accuracy of MR spectroscopy for detecting supratentorial neoplastic space-occupying lesions of the brain were 80.61% [95% CI: 71.69–87.22], 87.10% [95% CI: 71.15–94.87], 95.18% [95% CI: 88.25–98.11], 58.70% [95% CI: 44.34–71.71], and 82.17% [95% CI: 74.67–87.82], respectively

Conclusion: Magnetic Resonance Spectroscopy (MRS) offers a reliable non-invasive method for distinguishing brain lesions, reducing the need for biopsies and improving patient outcomes..

Keywords: Brain lesions, Medical resonance imaging, MRS, Space occupying lesion.

1. INTRODUCTION

Diagnosing benign and malignant intracranial lesions based solely on imaging methods remains challenging. Accurate diagnosis is critically important for the clinical management of patients with brain tumours [1]. When feasible, most tumours are surgically resected, balancing the removal of tumour tissue with the preservation of essential brain functions [2-3]. Conventional MR imaging offers high-resolution anatomical information and is regarded as the

primary first step in diagnosing suspected brain lesions [4].

Magnetic resonance spectroscopy (MRS) is a cutting-edge neuroimaging technique that provides non-invasive, real-time brain metabolite analysis. By selectively targeting a small tissue volume (voxel), MRS generates a spectrum reflecting the tissue's molecular composition, offering insights into cellular processes like proliferation, degradation, and energy metabolism [5-7]. This allows for improved differentiation between benign and malignant brain lesions. While MRI is widely used for tumour staging, treatment planning, and monitoring, its diagnostic accuracy for intracranial masses varies [8,9]. MRS, as demonstrated by Abbas et al., significantly enhances diagnostic precision, showing high sensitivity (90.69%) and specificity (97.34%) in identifying neoplastic lesions compared to histopathology [10].

Proton Magnetic Resonance Spectroscopy (MRS) is a safe, widely available, and non-invasive imaging tool that analyzes the brain's metabolic profile. Accurate differentiation between cancerous and non-cancerous brain lesions is crucial, as misdiagnosis can lead to inappropriate and harmful treatments. This study seeks to address the lack of local data by evaluating MRS's ability to characterize brain lesions compared to histopathology and to determine its accuracy in distinguishing between neoplastic and non-neoplastic conditions.

2. MATERIAL AND METHODS:

A cross-sectional study was conducted at Ziauddin Hospital's Radiology Department, employing consecutive non-probability sampling. Patients 20 to 70 years of age, either gender, referred for MR spectroscopy showing space-occupying lesions on conventional MRI were recruited. Permission from the institutional ethical review committee was taken before the conduct of the study. Informed consent was obtained from all the patients for assigning them to sample and using their data in research. A brief history of demographic information was taken. Patients with significant intra-lesional hemorrhage on SWI occupying more than 50% of the tumour size because of inappropriate metabolite values, lesions close to skull bone in which MRS is not possible and small size of lesion to voxel were excluded.

All patients will undergo MR spectroscopy and the findings were documented by the researcher under the supervision of a senior Neuro-radiologist with over ten years of experience and was labelled as having neoplastic space occupying a lesion of the brain. A space-occupying area showing perilesional oedema, mass effect, variable signal on spin-echo sequences and showing variable post-contrast enhancement. After the biopsy specimen histopathology was assessed for final diagnosis.

MR Spectroscopy: In special imaging modalities single voxel and multi-voxel is performed and values of choline/creatinine, NAA, Lipid, and lactate would be assessed. Normal choline peak is 3.2ppm, creatinine is 3.0ppm, NAA is 2.0ppm, Lipid is 1.3ppm, and Lactate is 1.33ppm. Neoplastic lesions were identified by increased choline, decreased NAA, and a Cho/Cr ratio above 1.5. Choline/NAA ratio above 2.5.

Sample size: Sample size was determined using Lin Naing's calculator for sensitivity and specificity. Considering an expected sensitivity of 90.69%, specificity of 97.34%, and prevalence of supratentorial neoplastic space-occupying lesions at 72.4%, [10] with a margin of error (d) set at 6%, the required sample size was determined to be 129 participants.

Data Analysis Procedure: SPSS version 22 was used for all statistical analyses. Continuous data, like age, were presented as mean \pm standard deviation (SD) if they followed a normal distribution, as determined by the Kolmogorov-Smirnov test. For non-normally distributed data, the median and interquartile range (IQR) were used.

Categorical variables, including gender and the presence of neoplastic space-occupying lesions on MR spectroscopy and histopathology (Positive/Negative), were reported as frequencies and percentages. Diagnostic performance measures, including sensitivity, specificity, positive predictive value (PPV), negative predictive value (NPV), and overall diagnostic accuracy of MR spectroscopy, were calculated using a 2 \times 2 contingency table, with histopathology as the gold standard."

Results:

This study involved 129 patients, with an average age of approximately 41 years, ranging from 21 to 69. The majority of participants were male (61%), and the average duration of their symptoms was roughly 8.5 weeks. Altered consciousness was the most frequently reported symptom (82.5%), followed by fever (21%) and a history of ear, nose, and throat (ENT) infections (15.5%). Regarding comorbidities, hypertension and diabetic mellitus were observed in 36.43% and 25.58% respectively. 29 of 129 patients (22.48%) were smokers. Demographic characteristics of the patients are shown in Table 1.

The most common tumour diagnosed on histopathology was low grade and high grade astrocytoma (40 cases, 31.01%), followed by oligodendroglioma (28 cases, 21.71%), glioblastoma (15 cases, 11.63%), and lymphoma (10 cases, 7.75%). Similarly, abscess and tuberculoma were the most common inflammatory lesions, as presented in Figure 1.

The prevalence of neoplastic space-occupying lesions was 75.97% [95% CI: 68.6%–83.3%]. The sensitivity, specificity, PPV, NPV, and diagnostic accuracy of MR spectroscopy for detecting supratentorial neoplastic space-occupying lesions of the brain were 80.61% [95% CI: 71.69–87.22], 87.10% [95% CI: 71.15–94.87], 95.18% [95% CI: 88.25–98.11], 58.70% [95% CI: 44.34–71.71], and 82.17% [95% CI: 74.67–87.82], respectively, as shown in Table 1 and Figure 2,3 and 4.

Table 1: Demographic characteristics of the patients (n=129)

Variables	Frequency (%)
Age Groups	
18-40	76(58.91%)
41-60	41(31.78%)
>60	12(9.30%)
Gender	
Male	79(61.24%)
Female	50(38.76%)
Comorbid	
Diabetic Mellitus	33(25.58%)
Hypertension	47(36.43%)
Smoking	29(22.48%)
Ischemic Heart Disease	09(7%)
Others	12(9.30%)

Figure 1: Types of lesions on histopathology (n=129)

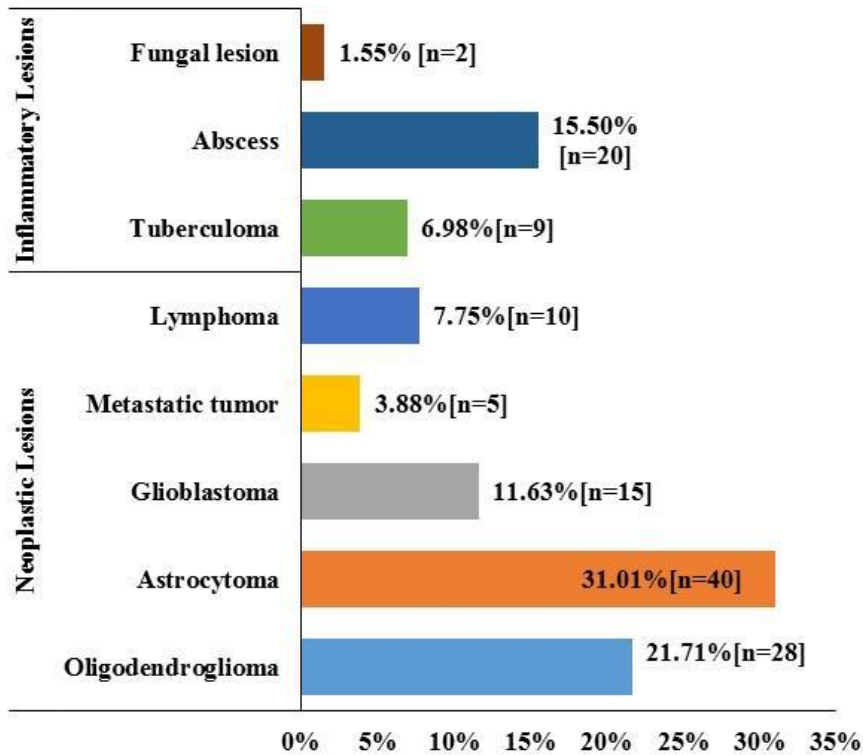


Table 2: diagnostic accuracy of MR spectroscopy for the detection of supra-tentorial neoplastic space-occupying lesion of the brain by taking histopathology as the gold standard

Parameter	n	Estimate (%)
True Positive	79	
True Negative	27	
False Positive	4	
False Negative	19	
Sensitivity (True Positive rate)	78/98	80.61 [71.69-87.22]
Specificity (True Negative Rate)	27/31	87.10 [71.15-94.87]
PPV (Precision)	79/83	95.18 [88.25-98.11]
NPV	27/46	58.70 [44.34-71.71]
Diagnostic Accuracy	(79+27)/129	82.17 [74.67-87.82]

Figure 2: MR Spectroscopy of high grade glioma. There is raised choline level and reduced NAA and creatinine level, choline/NAA ratio is more than 6.0 and choline/creatine ratio is more than 4.0.

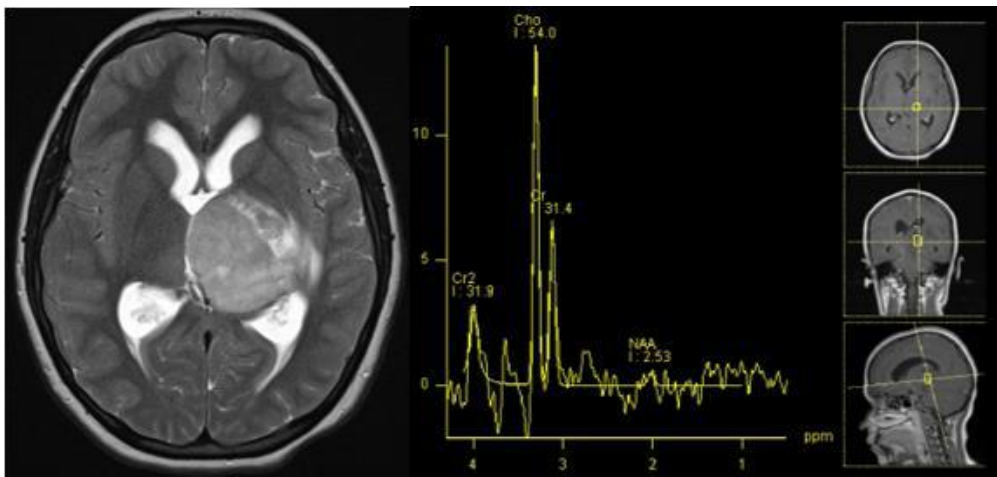


Figure 3: MR spectroscopy shows reduced peaks of choline, creatine and NAA peaks suggesting non-neoplastic disease process. This is a case of chronic encephalitis. There is evidence of raised lipid lactate peak that is likely secondary related to recent seizure activity.

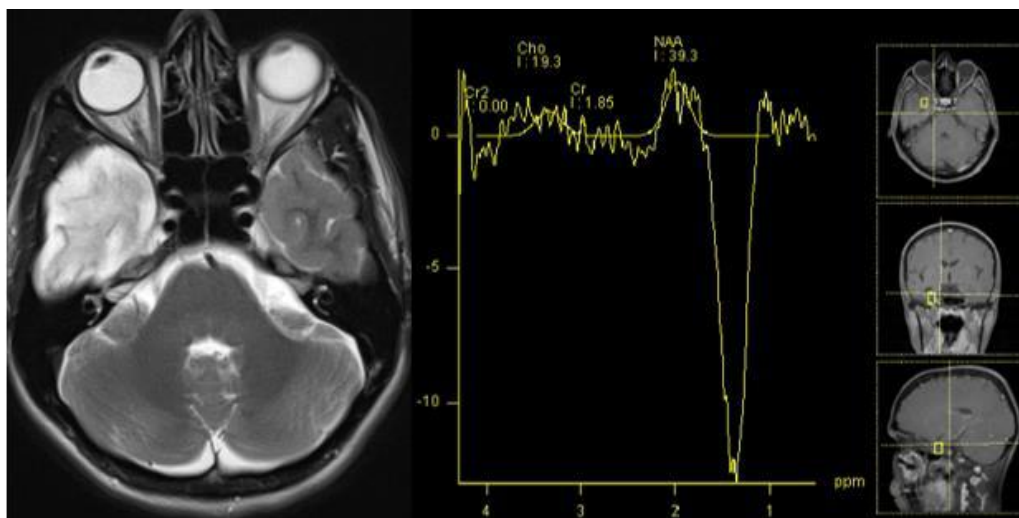
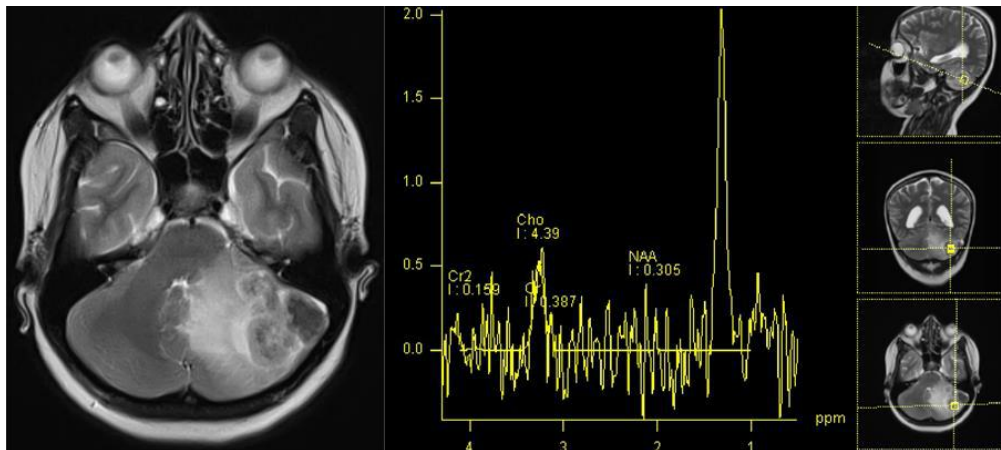


Fig 4. A case of cerebral tuberculosis. MR spectroscopy shows reduced peaks of choline, creatine and NAA.

3. DISCUSSION

Magnetic resonance spectroscopy (MRS) is invaluable for brain tumor assessment, assisting in grading and typing [11]. Tumor spectra diverge significantly from normal brain tissue, typically indicating decreased N-acetyl aspartate (NAA) and increased choline (Cho), leading to a higher Cho/NAA ratio. This reflects neuronal loss or dysfunction (NAA decrease) and enhanced cell membrane activity (Cho increase). Additionally, MRS can disclose elevated lactate, lipid, and myo-inositol levels in tumors [12]. MRS generally acts as an adjunct diagnostic tool when standard methods prove inadequate in clinical settings. Unlike research studies with controlled variables and focused questions, interpreting MRS data in these complex clinical cases, where patients present with varied and unclear diagnoses, is significantly more challenging.

In this study, the patient population was relatively young, with an average age The mean age was 40.68 years, with more males (61.24%) than females (38.76%). Studies examining similar patient populations show some variation in age and gender distribution. Musawar et al. [13] reported a mean patient age of approximately 41 years, with a predominance of males (69.3%). In contrast, Surur et al. [14] observed a female majority (57.9%) and a broader age range, averaging 35 years.

In the present study, an altered level of consciousness was the most common symptom in our patients (82.5%) followed by fever (20.9%) and a history of ENT infection (15.5%). Regarding comorbidities, hypertension and diabetic mellitus were observed in 36.43% and 25.58% respectively. 29 of 129 patients (22.48%) were smokers. The patient cohort primarily experienced headaches (91.1%), followed by seizures (50%), body weakness (41.9%), vertigo (31.25%), vomiting and decreased vision (30.35% each), and decreased hearing (24.1%) [15].

In this study, histological examination showed astrocytoma to be the most prevalent tumor, followed in frequency by oligodendroglioma, glioblastoma, and then lymphoma. In addition, abscesses and tuberculomas were the most commonly found inflammatory lesions. In Qadir et al.'s study [15] of neoplastic histopathology findings, oligodendroglioma (34.8%), astrocytoma (10.7%), glioblastomas (13.4%), metastatic tumors (9.8%), and lymphoma (7.1%) were observed. In cases of inflammation, tuberculoma (7.1%), abscess (11.6%), and fungal infection (5.3%) were noted.

The prevalence of neoplastic space-occupying lesions in the present study was 75.97%. The sensitivity, specificity, and diagnostic accuracy of MR spectroscopy for detecting supratentorial neoplastic space-occupying lesions of the brain were 80.61%, 87.10%, and 82.17%, respectively.

Rajasree et al. [16] concluded that MRS accurately differentiates malignant from benign focal brain lesions, with 87.5% sensitivity, 93.3% specificity, 95.5% PPV, 89.7% NPV, and 92.1% accuracy [13]. Musawar et al.'s r[13] research showed that MRS was highly sensitive (94.1%) and specific (88.0%) in diagnosing malignant lesions. A positive MRS result strongly indicated malignancy (97.0% PPV), while a negative result was less reliable in excluding it (78.6% NPV). Qadir et al. [15] found that a Cho/Cr ratio above 2, present in 82.4% of neoplastic lesions, yielded an MRS sensitivity of 82.4%, specificity of 70.4%, PPV of 87.4%, and NPV of 55.9%.

In the Alam et al. study [17], an MRS-based assessment of neoplastic brain lesions yielded 40 true positive, 3 false positive, 7 true negative, and 3 false negative results, resulting in a sensitivity of 93.02%, a specificity of 70%, a positive predictive value of 93.02%, a negative predictive value of 70%, and a diagnostic accuracy of 88.67%. In our study, there were 19 false negative and 4 false positive results. The Nisar et al. [18] study reported 78 true positive, 8 false positive, 30 false negative, and 41 true negative results. This resulted in a sensitivity of 72.20%, a specificity of 83.67%, a positive predictive value of 90.60%, a negative predictive value of 57.70%, and a diagnostic accuracy of 75.70%. The 30 false negative results in the

Nisar et al. study are higher compared to our study and the Alam et al. study [17], raising a significant concern due to the potential for delayed or missed diagnoses of actual neoplastic lesions.

MRS analysis faces two main obstacles: achieving uniform magnetic fields (field homogeneity) and isolating the target tissue (volume averaging). Field distortions, caused by materials like metals or variations in tissue composition, are common, particularly in the brain's temporal and frontal lobes. Additionally, contamination of the measured area by surrounding tissues, such as fat, can skew results.[19]

Our study's primary limitations stemmed from its exclusion of pediatric patients, preventing us from evaluating MRS performance in this age group. Additionally, the single-centre design restricted our sample size and limited the variables examined. The use of single-voxel MRS, instead of a multi-voxel approach, introduced potential inter-observer bias. Furthermore, our analysis was limited to a few metabolite ratios; a broader examination of individual metabolites and diverse ratios might have yielded more comprehensive diagnostic insights.

4. CONCLUSION

Neoplastic lesions, particularly astrocytomas, were the most common diagnoses, highlighting the importance of considering tumours in the differential diagnosis. MR spectroscopy demonstrated promising diagnostic accuracy for detecting supratentorial neoplastic lesions, with high sensitivity, specificity, and positive predictive value. MRS can be used non-invasively to differentiate neoplastic from inflammatory brain lesions. Its value is especially prominent in difficult cases, aiding in pre-operative diagnosis and early treatment.

REFERENCES

- [1] Alshammari QT, Salih M, Gameraddin M, Yousef M, Abdelmalik B, Loaz O. Accuracy of Magnetic Resonance Spectroscopy in Discrimination of Neoplastic and Non-Neoplastic Brain Lesions. *Curr Med Imaging*. 2021;17(7):904-10.
- [2] Seano G, Nia HT, Emblem KE, Datta M, Ren J, Krishnan S et al. Solid stress in brain tumours causes neuronal loss and neurological dysfunction and can be reversed by lithium. *Nat. Biomed. Eng*. 2019;3(3):230–45.
- [3] Nikmaneshi MR, Firoozabadi B, Mozafari A, Munn LL. A multi-scale model for determining the effects of pathophysiology and metabolic disorders on tumor growth. *Sci. Rep*. 2020;10(1):3025.
- [4] Nandu H, Wen PY, Huang RY. Imaging in neuro-oncology. *Ther. Adv. Neurol. Disorder*. 2018;11:1756286418759865.
- [5] Falk Delgado A, Van Westen D, Nilsson M, Knutsson L, Sundgren PC, Larsson EM et al. Diagnostic value of alternative techniques to gadolinium-based contrast agents in MR neuroimaging-a comprehensive overview. *Insights Imaging*. 2019;10(1):84.
- [6] Mandal PK. Magnetic Resonance Spectroscopy (MRS) and its application in Alzheimer's disease. *Concepts Magn Reson Part A*. 2007;30A:40–64.
- [7] Abdel-Monem ND, Manal EB, Manal H, Noha S. Magnetic resonance spectroscopy and diffusion imaging in the evaluation of neoplastic brain lesions. *The Egyptian Journal of Radiology and Nuclear Medicine*. 2014;45:485- 93.
- [8] Bertholdo D, Watcharakorn A, Castillo M. Brain proton magnetic resonance spectroscopy: introduction and overview. *Neuroimaging Clin N Am*. 2013;23:359-80.
- [9] Kostas N., Fountas; Proton Magnetic Resonance Spectroscopic Imaging Can Predict Length of Survival in Patients with Supratentorial Gliomas. *Neurosurgery*. 2004;55:257-58.
- [10] Abbas A, Javeed F, Rehman L, Afzal A, Rizvi Rk. Magnetic Resonance Spectroscopic and Histopathological Findings in the Supratentorial Brain Space Occupying Lesions. *Pak J Neurol Surgery*. 2020 Sep 25;24(3):210-5.
- [11]
- [12] Shokry A. MRS of brain tumors: Diagrammatic representations and diagnostic approach. *The Egyptian Journal of Radiology and Nuclear Medicine*. 2012; 43(4):603-12.
- [13] Ahmed NGM, Aamin A, Khalifa S, Elhassan SM, Albashir M, Ahmed M, et al. Characterization of brain lesions using magnetic resonance spectroscopy. 2021.
- [14] Musawar S, Ayyaz AS, Manzoor A, Manzoor I. Diagnostic accuracy of magnetic resonance spectroscopy (MRS) for diagnosis of focal brain lesions taking histopathology as gold standard. *Professional Med J* 2022; 29(11):1740-1744.
- [15] Surur A, Cabral JF, Marangoni A, Marchegiani S, Palacios C, Herrera E, et al. Contributions of magnetic

resonance spectroscopy in brain lesions. RAR. 2010; 74(3):239-49.

- [16] Qadir R, Rehman L, Bokhari I, Shah RA, Qasim A, Aroqi YA, Hasan M. Role of magnetic resonance spectroscopy in supratentorial brain lesions. Pakistan Journal of Medical & Health Sciences. 2023 Mar 10;17(02):176-.
- [17] Rajasree D, Kumar TL, Vijayalakshmi K. Role of magnetic resonance spectroscopy in the evaluation of ring-enhancing lesions of the brain. Journal of Clinical & Diagnostic Research. 2020; 14(10)
- [18] Alam MS, Ahsan H, Sajjad Z, Beg M, Bhatti U, Enam A, et al. Magnetic resonance spectroscopy of enhancing cerebral lesions: Analysis of 78 histopathology proven cases. JPMA The Journal of the Pakistan Medical Association. 2014; 64(10):1141.
- [19] Nisar SA, Rauf MA, Sarfraz LU. Diagnostic Accuracy (sensitivity and specificity) of Magnetic Resonance Spectroscopy as an imaging tool in the differentiation of benign vs malignant intracranial space occupying lesions. PJMHS. 2020;14(3):528.
- [20] Mullins ME. MR spectroscopy: truly molecular imaging; past, present and future. Neuroimaging Clinics. 2006; 16(4):605-18.