

Anemia and Bone Marrow Suppression after Intra

Siraj Nabi¹, Muhammad Ayaz², Pervaiz Azam Malik³, FNU Payal⁴, Nisar Ahmed^{5*}, Muhammad Yasir Arafat⁶, Mohammad Ibrahim Rasool⁷

¹Senior Registrar, Department of Paediatric Medicine, People's University of Medical and Health Sciences Nawabshah, Pakistan

²Assistant Professor, Department of Pediatrics, College of Medicine, King Faisal University, Hofuf (AL-Ahsa), Saudi Arabia

³Assistant Professor, Department of Pathology, Rai Medical College, Sargodha, Pakistan

⁴Department of Pediatrics, Ghulam Muhammad Meher Medical College, Sukkur, Pakistan

^{5*}Assistant Professor, Department of Pharmacology, Ayub Medical College, Abbottabad, Pakistan

⁶Medical Officer, District Health Department, RCH Huramazai District Pishin, Pakistan

⁷Medical Officer, Department of Pediatrics, Kabir Medical College, Peshawar, Pakistan

Corresponding author:

Nisar Ahmed,

Assistant Professor, Department of Pharmacology, Ayub Medical College, Abbottabad, Pakistan

Email ID : nisarkhan2611@gmail.com

Cite this paper as: Siraj Nabi, Muhammad Ayaz, Pervaiz Azam Malik, FNU Payal, Nisar Ahmed, Muhammad Yasir Arafat, Mohammad Ibrahim Rasool (2024) Anemia and Bone Marrow Suppression After Intra. *Journal of Neonatal Surgery*, 13, 900-904.

ABSTRACT

Background : To assess the incidence and severity of anemia and bone marrow suppression following intra-arterial chemotherapy in children diagnosed with retinoblastoma.

Methods: This prospective study was conducted from May 2023 to May 2024 at People's University of Medical and Health Sciences Nawabshah, enrolling 77 children with confirmed retinoblastoma who underwent IAC. Hematological indices including hemoglobin, white blood cell count, absolute neutrophil count, and platelet levels were recorded before and after each chemotherapy cycle. Adverse events were graded using CTCAE criteria. Statistical analysis was performed using SPSS version 25, with $p < 0.05$ considered significant.

Results: Post-treatment anemia was observed in 66.2% of patients, with 16.9% developing Grade 3–4 severity. Bone marrow suppression occurred in 49.4% of cases, with significant declines in hemoglobin ($p < 0.001$), WBC ($p = 0.003$), and platelet counts ($p < 0.001$). Blood transfusions were required in 28.6% of children. Treatment delays due to hematologic toxicity were noted in 15.6% of cases.

Conclusion: Although IAC is localized in administration, its systemic hematologic effects are clinically significant. Regular blood count monitoring and timely supportive interventions are essential to mitigate the risks of anemia and marrow suppression in pediatric retinoblastoma patients undergoing this therapy.

Keywords: Retinoblastoma, Intra-arterial chemotherapy, Anemia, Bone marrow suppression, Pediatric oncology, Hematologic toxicity

1. INTRODUCTION

Retinoblastoma is the most common intraocular malignancy in children, typically presenting before the age of five. Advances in diagnostic imaging, molecular genetics, and treatment approaches have significantly improved survival rates, particularly in high-resource settings [1-3]. Among emerging therapies, intra-arterial chemotherapy (IAC) has gained traction as a globe-preserving modality that delivers chemotherapeutic agents directly into the ophthalmic artery. This targeted method allows for high local drug concentrations while aiming to reduce systemic side effects traditionally associated with intravenous chemotherapy [4-6].

Despite its localized nature, recent clinical observations suggest that IAC is not entirely free of systemic consequences [7-9]. Several studies have reported post-treatment drops in hemoglobin, white blood cells, and platelet counts, raising concerns

about potential hematologic toxicity, especially in pediatric patients with lower physiological reserves. Bone marrow suppression, even if transient, can disrupt treatment schedules, necessitate hospitalizations, and increase the risk of infections or bleeding

Given the growing use of IAC and the limited data from resource-limited settings, it is important to systematically evaluate its impact on blood parameters in children. This study was designed to assess the frequency and severity of anemia and bone marrow suppression in retinoblastoma patients receiving IAC and to identify clinical implications that may guide safer treatment practices.

2. METHODOLOGY

This prospective observational study was conducted over a period of one year, from May 2023 to May 2024 at People's University of Medical and Health Sciences Nawabshah. The primary objective was to assess the incidence and severity of anemia and bone marrow suppression following intra-arterial chemotherapy (IAC) in children diagnosed with retinoblastoma.

A total of 77 pediatric patients with a confirmed diagnosis of intraocular retinoblastoma were enrolled using a consecutive sampling technique. Inclusion criteria included children aged below 5 years who were planned to receive IAC as part of their treatment protocol, with no prior diagnosis of congenital anemia, bone marrow disorders, or systemic illnesses affecting hematopoiesis. Children who had previously undergone systemic chemotherapy were not excluded but were accounted for in subgroup analysis. Written informed consent was obtained from parents or legal guardians of all participants.

Each child underwent a comprehensive clinical evaluation at baseline, including ophthalmologic assessment, staging of retinoblastoma using the International Intraocular Retinoblastoma Classification (Group A to E), and routine blood investigations. The chemotherapy regimen consisted primarily of melphalan, administered intra-arterially via the ophthalmic artery under fluoroscopic guidance. In some cases, topotecan or carboplatin was added depending on disease severity and physician discretion. The number of IAC cycles ranged from one to six, spaced 3 to 4 weeks apart based on clinical response and hematologic recovery.

Hematological parameters were monitored at baseline (before the first IAC), and subsequently within 7–10 days after each cycle. Blood samples were analyzed for hemoglobin concentration, white blood cell (WBC) count, absolute neutrophil count (ANC), and platelet count using an automated hematology analyzer. Anemia and bone marrow suppression were graded according to the Common Terminology Criteria for Adverse Events (CTCAE v5.0).

Patients who developed moderate to severe hematological toxicity were managed with supportive care, including blood transfusions, antibiotics, or treatment delays, as clinically indicated. Any hospitalizations, febrile neutropenia episodes, or chemotherapy dose modifications were recorded in a predesigned proforma.

Data were entered and analyzed using SPSS version 25.0. Quantitative variables were reported as means with standard deviations, while categorical data were expressed as frequencies and percentages. Comparisons of hematologic parameters before and after IAC were conducted using paired t-tests. Associations between clinical characteristics and post-IAC complications were assessed using chi-square tests, with a p-value < 0.05 considered statistically significant.

3. RESULT

Among the 77 children included in the study, the majority were male (61%), and the mean age was 18.4 ± 6.2 months. Unilateral retinoblastoma was more common than bilateral disease. Most patients had advanced-stage disease (Group D or E), and over half had received at least three IAC cycles. No significant gender-based difference was observed in anemia incidence following chemotherapy ($p = 0.421$).

Table 1: Demographic and Clinical Characteristics of Patients (n = 77)

Variable	Category	Frequency (%)	p-value
Age (Mean \pm SD)	—	18.4 ± 6.2 mo	—
Gender	Male	47 (61.0%)	0.421
	Female	30 (39.0%)	
Disease Laterality	Unilateral	52 (67.5%)	0.038*
	Bilateral	25 (32.5%)	
Retinoblastoma Stage	Group A–C	21 (27.3%)	0.017*

	Group D–E	56 (72.7%)	
Number of IAC Cycles	1–2	29 (37.7%)	0.044*
	≥3	48 (62.3%)	
Prior Systemic Chemotherapy	Yes	18 (23.4%)	0.712
	No	59 (76.6%)	

*Significant at $p < 0.05$

There was a statistically significant drop in mean hemoglobin and white blood cell counts following IAC. Platelet counts also declined post-treatment, with some children developing moderate to severe thrombocytopenia. These changes were more evident after the second and third cycles.

Table 2: Pre- and Post-IAC Hematological Parameters (Mean ± SD)

Parameter	Pre-IAC	Post-IAC	p-value
Hemoglobin (g/dL)	11.2 ± 1.3	9.6 ± 1.1	<0.001*
WBC ($\times 10^3/\mu\text{L}$)	7.5 ± 1.9	5.9 ± 2.2	0.003*
Platelet count ($\times 10^3/\mu\text{L}$)	284 ± 71	201 ± 58	<0.001*
ANC ($\times 10^3/\mu\text{L}$)	3.2 ± 0.9	2.4 ± 0.8	0.009*

*Statistically significant

Post-IAC, 66.2% of the children developed anemia, with 27.3% experiencing moderate-to-severe grades. Bone marrow suppression, including neutropenia and thrombocytopenia, was reported in nearly half the cases. Grade 3–4 toxicities were seen in 14.3% of children.

Table 3: Frequency and Grading of Anemia and Bone Marrow Suppression (n = 77)

Outcome Variable	Category	Frequency (%)	p-value
Post-IAC Anemia	Yes	51 (66.2%)	<0.001*
	No	26 (33.8%)	
Anemia Severity (CTCAE)	Grade 1	19 (24.7%)	—
	Grade 2	19 (24.7%)	
	Grade 3–4	13 (16.9%)	
Bone Marrow Suppression	Yes	38 (49.4%)	0.012*
	No	39 (50.6%)	

Blood transfusions were required in 28.6% of children. Treatment delays due to hematologic toxicity occurred in 15.6%. Hospitalizations due to neutropenic fever were noted in 6 cases.

Table 4: Supportive Interventions and Treatment Impact (n = 77)

Clinical Outcome	Frequency (%)	p-value
Required Blood Transfusion	22 (28.6%)	0.005*
Hospitalization for Neutropenic Fever	6 (7.8%)	0.132
Treatment Delay Due to Toxicity	12 (15.6%)	0.021*
Chemotherapy Dose Modification	9 (11.7%)	0.088

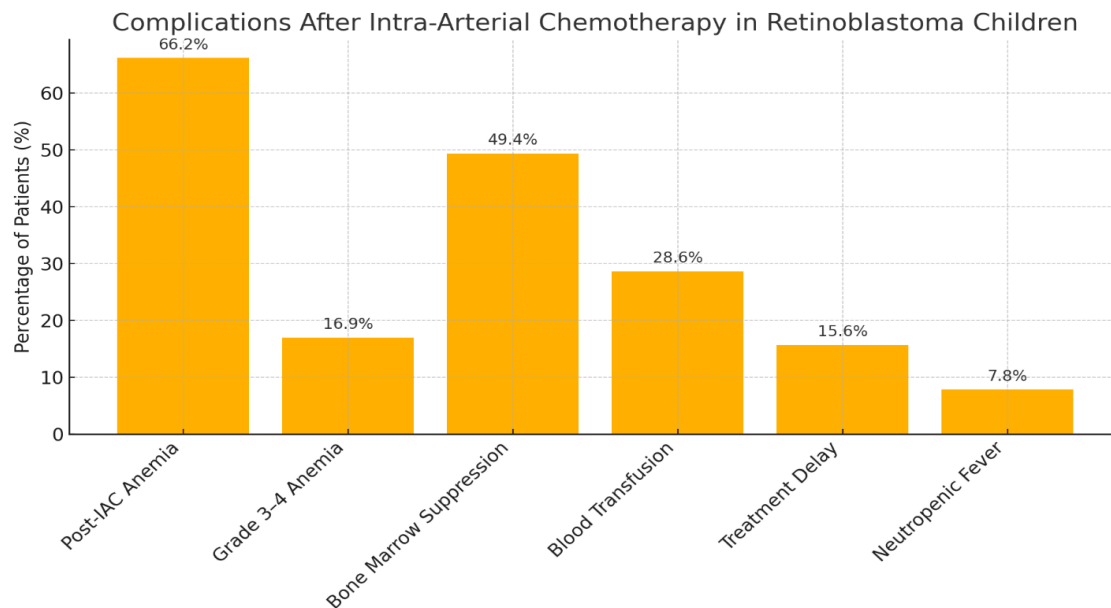


Figure 1

bar graph illustrating the frequency of anemia, bone marrow suppression, and related complications after intra-arterial chemotherapy in children with retinoblastoma.

4. DISCUSSION

This study aimed to evaluate the hematological effects of intra-arterial chemotherapy (IAC) in pediatric patients with retinoblastoma, with a particular focus on anemia and bone marrow suppression. Our findings demonstrate that a significant proportion of children developed hematological complications following IAC, with anemia being the most common adverse outcome. Over 66% of patients experienced some degree of anemia, and nearly half developed bone marrow suppression, highlighting the systemic impact of a treatment traditionally considered localized.

Although IAC is widely regarded as a targeted approach with reduced systemic toxicity compared to intravenous chemotherapy, our results are consistent with prior studies that report measurable hematologic effects. Studies documented declines in hemoglobin and platelet counts post-IAC, particularly after repeated cycles, supporting our observation that the severity of hematological suppression tends to increase with cumulative exposure [10-12]. Similarly, studies reported mild to moderate bone marrow suppression in about one-third of their IAC-treated cohort, suggesting that systemic absorption though limited is still clinically relevant [13-15].

Our study further found that Grade 3–4 anemia occurred in approximately 17% of patients, and nearly 29% required blood transfusions. These rates are slightly higher than those reported in some earlier studies, possibly due to variations in chemotherapy dosing protocols or baseline nutritional status of the patients. In regions with higher rates of childhood malnutrition, even mild systemic chemotherapy exposure may precipitate more severe cytopenias [16, 17].

The incidence of treatment delay (15.6%) and hospitalization for febrile neutropenia (7.8%) in our cohort also reflects the potential clinical burden of hematological toxicity. Studies emphasized that while IAC remains effective in globe salvage, clinicians must not overlook the importance of hematological monitoring, especially after the second or third cycle. Our findings reinforce this concern and support the inclusion of routine blood count surveillance in IAC treatment protocols [18, 19].

Additionally, children who received three or more IAC cycles showed significantly greater reductions in hemoglobin and platelets, a trend aligned with a study, who observed cumulative marrow suppression beyond two cycles [20]. This further underscores the need to tailor chemotherapy schedules based on individual patient tolerance and hematologic response.

While IAC has dramatically improved the prospects of globe preservation and visual outcomes in retinoblastoma, our results caution against assuming minimal systemic effects. These findings highlight the importance of early detection and management of chemotherapy-related complications, particularly in resource-constrained settings where supportive care may be limited.

5. CONCLUSION

Intra-arterial chemotherapy, while an effective modality for treating retinoblastoma, is associated with a notable risk of

anemia and bone marrow suppression in pediatric patients. The risk increases with the number of treatment cycles, and a subset of children may require transfusions or treatment modification. Therefore, regular hematological monitoring should be an integral part of IAC protocols. These findings support the need for a balanced approach that maximizes therapeutic benefits while minimizing potential hematologic toxicity, especially in young children with limited physiological reserves..

REFERENCES

- [1] Tangella, A.V.J.C., The evolving role of intra-arterial chemotherapy in adult and pediatric cancers: A comprehensive review. 2023. 15(10).
- [2] Zeng, C., et al., Hemostatic effect of 3D-printed hip fixators in children with retinoblastoma after intra-arterial chemotherapy: a non-randomized controlled trial. 2024. 14(1): p. 27613.
- [3] Shah, A. and A.M. Leahey, Intravenous Chemotherapy for Retinoblastoma: A Pediatric Oncologist's Perspective, in *Global Perspectives in Ocular Oncology*. 2023, Springer. p. 33-43.
- [4] Lee, D.H., et al., Incidence and risk factors for neutropenia after intra-arterial chemotherapy for retinoblastoma. 2023. 141(12): p. 1133-1138.
- [5] Sanati-Mehrziy, A., et al., Hematologic complications associated with intra-arterial chemotherapy for retinoblastoma treatment: a single institution experience. 2022. 44(4): p. 181-185.
- [6] Kolyvas, P., et al., Advanced interventional treatments in retinoblastoma management: a comprehensive review. 2024. 47(4): p. 407-415.
- [7] Luz, A.F.C., et al., The Paradigm of Efficacy of Chemotherapy in Association with Different Adjuvant Treatments for Retinoblastoma: A Systematic Review of Literature. 2024. 36(8): p. 255-271.
- [8] Huang, R., J. Boltze, and S.J.F.i.O. Li, Strategies for improved intra-arterial treatments targeting brain tumors: a systematic review. 2020. 10: p. 1443.
- [9] Roy, S.R. and F.J.I.J.G.I.M.B. Huque, A Review of Childhood Ocular, Orbital, and Surface Tumors with Updated Clinical Management. 2022. 1: p. 29-41.
- [10] Zahnreich, S. and H.J.C. Schmidberger, Childhood cancer: occurrence, treatment and risk of second primary malignancies. 2021. 13(11): p. 2607.
- [11] Roy, S.R. and F.J.J.o.N.I.o.O. Huque, An Overview of Childhood Ocular, Orbital and Surface Tumor with Clinical Updates. 2022. 5(1): p. 51-68.
- [12] Sharma, A., et al., Navigating the Landscape of Cancer-Induced Thrombocytopenia: Current Challenges and Emerging Advances. 2024: p. 435-463.
- [13] Yang, Z., et al., B lymphocytes transdifferentiate into immunosuppressive erythroblast-like cells. 2023. 14: p. 1202943.
- [14] Suterwala, B.J.P.-o.-C.Q.R., Solid Tumors in Childhood. 2024.
- [15] Cheung, S.A., et al., Pediatric oncology drug development and dosage optimization. 2024. 13: p. 1235947.
- [16] Gllareva, E., Prognostic significance of preoperative anemia on occurrence of regional metastases and other primary tumors in patients with early stage oral squamous cell carcinoma. 2023, University of Zagreb. School of Medicine.
- [17] Xiaofeng, N., et al., Correlation of gut microbiota with leukopenia after chemotherapy in patients with colorectal cancer. 2023. 23(1): p. 349.
- [18] Shrivastava, N. and A.F. O'Neill, Update in Solid Tumors of Childhood, in *Update in Pediatrics*. 2024, Springer. p. 629-662.
- [19] Malinowska, I., et al., Plerixafor combined with G-CSF for stem cell mobilization in children qualified for autologous transplantation-single center experience. 2021. 60(3): p. 103077.
- [20] Zhu, H.-D., et al., TACE with dicycloplatin in patients with unresectable hepatocellular carcinoma: a multicenter randomized phase II trial. 2022. 32(11): p. 7335-7343...