

Ideal Time for Preoperative Use of Indocyanine Green Dye in Laparoscopic Cholecystectomy An Observational Study at A Tertiary Care Hospital

Dr. Manoj Togale^{1*}, Dr. Abhishek Gogate¹, Dr. Abhijit Gogate¹, Dr. Pavan Kumar Lekkala¹, Dr. Ayushman Sharma¹

¹Department of General Surgery, Jawaharlal Nehru Medical College Belgaum India

***Corresponding author:**

Dr. Abhishek Gogate

Department of Chest Surgery, Institute of Chest Surgery Medanta, India

Email ID: abhishekgogate4@gmail.com

Cite this paper as: Dr. Manoj Togale, Dr. Abhishek Gogate, Dr. Abhijit Gogate, Dr. Pavan Kumar Lekkala, Dr. Ayushman Sharma, (2025) Ideal Time for Preoperative Use of Indocyanine Green Dye in Laparoscopic Cholecystectomy An Observational Study at A Tertiary Care Hospital. *Journal of Neonatal Surgery*, 14 (32s), 7861-7869.

1. INTRODUCTION

Gall stone disease is one of the most common pathology encountered in the surgical wards these days, With 10-15%¹ of the general population suffering from symptomatic or asymptomatic cholelithiasis, which makes it one of the most common pathology of the gall bladder and biliary tree. In Patients suffering from asymptomatic cholelithiasis it had recently discovered that the risk of developing symptoms or complications is 1-2% per year with 20% of them developing a symptomatic disease at a 15 year follow up.

Various treatment modalities have been employed for the treatment of cholelithiasis, with cholecystectomy being the standard line of treatment for the same.

Laparoscopic cholecystectomy is the most preferred approach for cholecystectomy and is considered as a the Gold standard procedure¹. Overall the incidence of cholelithiasis on a rise, the overall rates of laparoscopic cholecystectomies are rising rapidly.

However with the escalation in cholecystectomies and the transition from open to laparoscopic approach have correlated with a concomitant rise in bile duct injuries²

Frequent and substantial variations, typically ranging from 30% to 40% are frequently observed in the anatomical configuration of the biliary tree.^{3,4} Furthermore, the formation of adhesions in and around the calot's triangle due to diverse factors is a well-documented phenomenon⁵

These factors give rise to complexities in the precise intraoperative delineation of biliary anatomy, representing a prevalent challenge encountered by surgeons during laparoscopic cholecystectomy. These variations and difficulties in identifying the biliary anatomy increases the possibility of dreaded complications like bile duct injury and post-operative bile leak etc² ICG dye is a novel method used for visualization of biliary tree anatomy during laparoscopic cholecystectomy. Various studies have been undertaken to determine the effectivity of ICG in delineating the biliary anatomy in cases of cholecystectomies ()

ICG is a water-soluble tricarboyanine dye that binds to albumin and distributes rapidly and uniformly in the blood after **intravenous injection** and is exclusively secreted into the bile via hepatic parenchymal cells. ICG has a considerable fluorescence when illuminated by near infrared light with peak fluorescence at about 830 nm. This property of ICG is used to identify biliary anatomy intraoperatively using special near infrared cameras.

However the ideal time for preoperative use of ICG is not yet clearly identified, with the hyperillumination of liver proving to be a significant drawback in clear identification of biliary anatomy. Multiple studies have used ICG upto 3 hrs prior to surgery, however Boogerd et al., all concluded that highest bile duct-to-liver fluorescence ratio was achieved 3 to 7 hours after administration of dye.

Hence this study was undertaken aims to provide better understanding into the ideal time for preoperative use of ICG.

2. AIM

1. To determine the ideal time for pre-operative use of indocyanine green dye for better delineation of biliary anatomy in cases of laparoscopic cholecystectomies

Inclusion Criteria:

- 1). Patient undergoing laparoscopic cholecystectomy for symptomatic cholelithiasis and cholecystitis
- 2). Patient age > 18 yrs of age
- 3). ASA classification of physical status 1 or 2 with normal kidney and liver functions

Exclusion Criteria:

- 1). Patient with liver cirrhosis or in liver failure
- 2) Patients with history of Hepatitis B and C
- 3) Patient with history of allergy to the dye
- 4) Patient undergoing laparoscopic cholecystectomy for diseases other than symptomatic cholelithiasis and cholecystitis

3. MATERIALS AND METHOD

The study was performed in the inpatient department of a tertiary care hospital at Jawaharlal Nehru medical college India

The patients undergoing laparoscopic cholecystectomies were randomly divided into two groups with group A receiving the dye 30mins to 3hrs pre-operatively where as group B received the dye 3-6 hrs preoperatively.

25mg of the dye was diluted with 10ml distilled water .

All the patients received a full dose of 2.5mg (ie-1ml) indocyanine green dye (Trade name AUROGREEN) intravenously via a microfilter , 5 minutes after a test dose of 0.1ml

All the patients underwent a standard 4 port American technique of laparoscopic cholecystectomy⁶. STRYKER 1588 and 1688 NIRF laparoscopic camera was used for performing the surgery. Whenever surgeon considered it necessary the NIRF angiography with ICG was utilized intraoperatively.

The identification of structures was confirmed by the operating surgeon and assisting surgeon and the data was tabulated

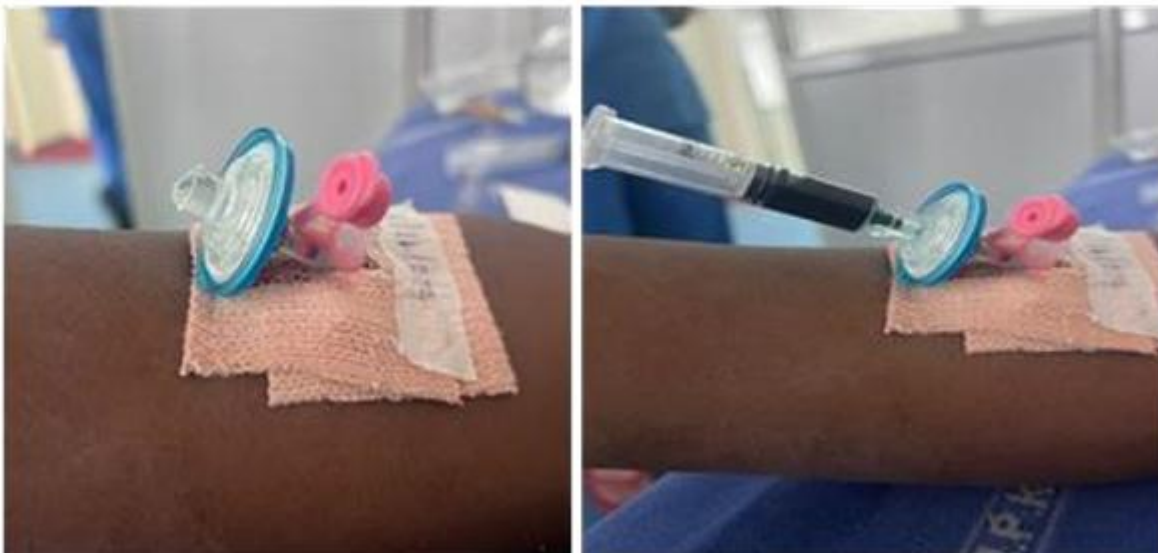

Image Intravenous Injection of ICG – preoperatively

4. RESULTS

Data contains measurements on 34 subjects where 17 (50%) belonged to group A and 17 (50%) belonged to group B. The following table gives the comparison of different variables over groups.

Table 1: Comparison of different variables over groups.

Variables	Sub Category	Groups		Total	p-value
		A	B		
Age	Mean ± SD	44 ± 16	46.59 ± 15.62	45.29 ± 15.62	0.6363 ^t
	Median (Min, Max)	40 (25, 70)	47 (22, 78)	45 (22, 78)	
Sex	Female	11 (64.71%)	11 (64.71%)	22 (64.71%)	1 ^c
	Male	6 (35.29%)	6 (35.29%)	12 (35.29%)	
Weight	Mean ± SD	69.35 ± 10.24	68.53 ± 5.5	68.94 ± 8.11	0.7727 ^{Wt}
	Median (Min, Max)	70 (48, 82)	68 (56, 79)	69.5 (48, 82)	
Height	Mean ± SD	162.35 ± 7.7	161.82 ± 7.19	162.09 ± 7.34	0.8371 ^t
	Median (Min, Max)	160 (151, 178)	161 (146, 174)	160 (146, 178)	
Acute Cholecystitis	No	9 (52.94%)	8 (47.06%)	17 (50%)	0.7316 ^C
	Yes	8 (47.06%)	9 (52.94%)	17 (50%)	
Choledocholithiasis	No	17 (100%)	14 (82.35%)	31 (91.18%)	0.2334 ^{MC}
	Yes	0 (0%)	3 (17.65%)	3 (8.82%)	

The study included a total of 34 participants with a median age of 45. They were randomly divided into the study groups. Both the groups were comparable in demographic characteristics like age, sex, weight and height.

In Group A, 8 patients, and in Group B, 9 patients had a prior history of acute cholecystitis and were undergoing an interval cholecystectomy. Additionally, 3 patients in Group B had a prior history of choledocholithiasis and had undergone ERCP with stenting prior to cholecystectomy. Both indications were statistically comparable.

Table 2 – Identification of structures

Identification of Cystic Duct	No	4 (23.53%)	2 (11.76%)	6 (17.65%)	0.6662 ^{MC}
	Yes	13 (76.47%)	15 (88.24%)	28 (82.35%)	
Identification of CBD	No	6 (35.29%)	2 (11.76%)	8 (23.53%)	0.2374 ^{MC}
	Yes	11 (64.71%)	15 (88.24%)	26 (76.47%)	
Identification of Hepatic Duct	No	9 (52.94%)	2 (11.76%)	11 (32.35%)	0.028 ^C
	Yes	8 (47.06%)	15 (88.24%)	23 (67.76%)	
Illumination of Liver	No	0 (0%)	10 (58.82%)	10 (29.41%)	0.0002 ^{C*}
	Yes	17 (100%)	7 (41.18%)	24 (70.59%)	
Identification of Cystic Artery	No	6 (35.29%)	3 (17.65%)	9 (26.47%)	0.4603 ^{MC}
	Yes	11 (64.71%)	14 (82.35%)	25 (73.53%)	
Total time of Surgery	Mean ± SD	65.12 ± 25.41	68.71 ± 31.51	66.91 ± 28.24	0.5932 ^{MW}
	Median (Min, Max)	60 (38, 134)	68 (18, 163)	63 (18, 163)	
Time to Identify Critical Angle of Safety	Mean ± SD	23.81 ± 11.95	23.69 ± 15.66	23.75 ± 13.7	0.9799 ^t
	Median (Min, Max)	24 (0, 44)	21.5 (0, 54)	22.5 (0, 54)	

Conversion to Open	No	15 (88.24%)	17 (100%)	32 (94.12%)	0.4973 ^{MC}
	Yes	2 (11.76%)	0 (0%)	2 (5.88%)	
Post-operative Bile Leak	No	17 (100%)	16 (94.12%)	33 (97.06%)	>0.9999 ^{MC}
	Yes	0 (0%)	1 (5.88%)	1 (2.94%)	
Type of Surgery Performed	Cholecystectomy	15 (88.24%)	16 (94.12%)	31 (91.18%)	0.4888 ^{MC}
	Lap subtotal cholecystectomy	0 (0%)	1 (5.88%)	1 (2.94%)	
	Open subtotal cholecystectomy	2 (11.76%)	0 (0%)	2 (5.88%)	

Identification of Structures

The identification rates of key anatomical structures, including the cystic duct, common bile duct (CBD), hepatic duct, and cystic artery, were assessed. The cystic duct was successfully identified in 76.47% of patients in Group A and 88.24% in Group B, the identification rates were comparable with a p-value of 0.6662, indicating no statistically significant difference. Similarly, the CBD was identified in 64.71% of Group A and 88.24% of Group B ($p = 0.2374$), also showing no significant variation. However, identification of the hepatic duct was significantly higher in Group B (88.24%) compared to Group A (47.06%), with a p-value of 0.028, favoring Group B.

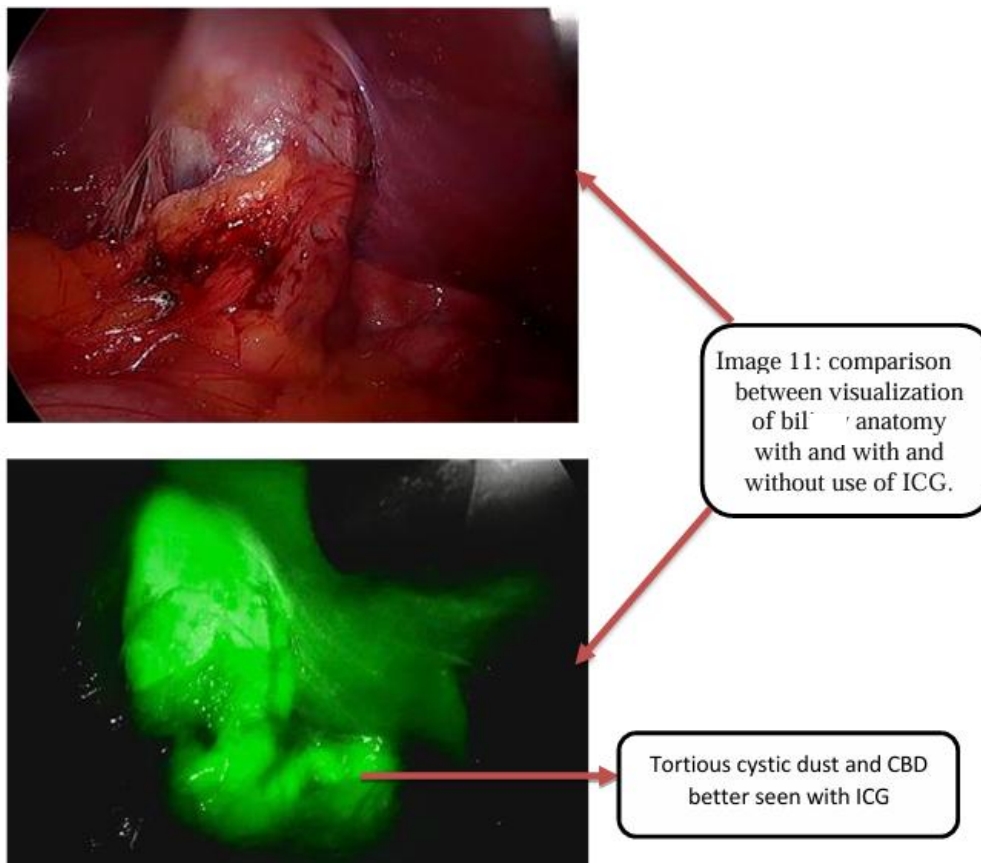


Image- Identification of Biliary structures using ICG

Liver Illumination

A substantial difference was observed in liver illumination. All patients in Group A (100%) had illumination of liver in the background, whereas only 41.18% of those in Group B had a background liver illumination. This difference was statistically significant ($p = 0.0002$).

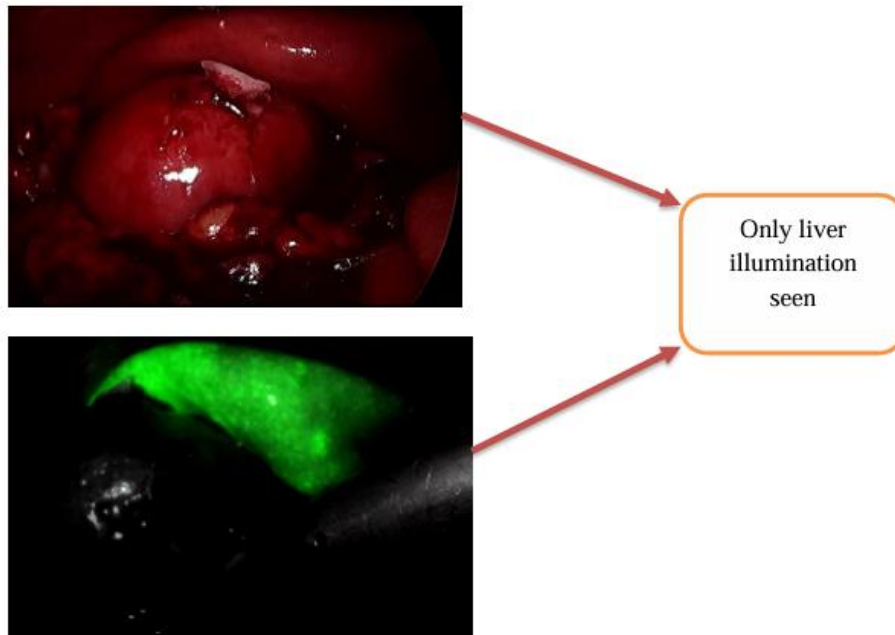


Image- Group A Gall bladder not visualized 45 minutes after dye insertion

Surgical Duration and Critical Angle of Safety

The time was calculated from the retraction of call bladder over the liver bed to the achievement of critical view of safety. The overall duration of surgery was comparable between the two groups, with a mean of 65.12 ± 25.41 minutes in Group A and 68.71 ± 31.51 minutes in Group B ($p = 0.5932$). Likewise, the time required to identify the critical angle of safety was nearly identical between the groups ($p = 0.9799$).

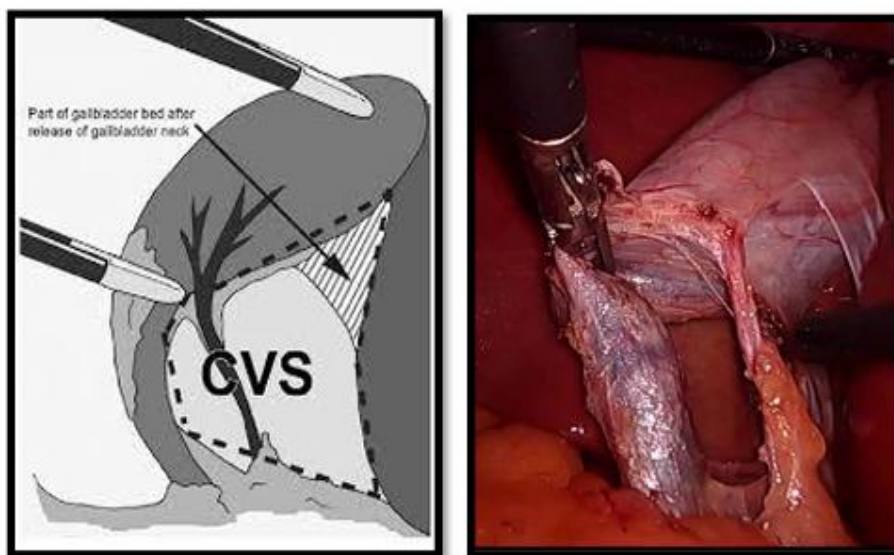


Image- Critical View of safety

Conversion to Open Surgery and Postoperative Outcomes

The rate of conversion to open surgery was slightly higher in Group A (11.76%) compared to Group B (0%), though this difference was not statistically significant ($p = 0.4973$). Postoperative bile leaks occurred in 1 (2.94%) case in group B, with no meaningful difference between the groups ($p > 0.9999$).

Table 3 – biochemical parameters

Hemoglobin	Mean ± SD	12.68 ± 1.67	12.29 ± 1.46	12.49 ± 1.56	0.4837 ^t
	Median (Min, Max)	12.7 (10, 15.7)	12.1 (8.3, 14.5)	12.3 (8.3, 15.7)	
Total Leucocyte Count	Mean ± SD	8158.82 ± 2520.43	9102.35 ± 3433.19	8630.59 ± 3004.02	0.5932 ^{MW}
	Median (Min, Max)	7600 (5800, 17000)	8000 (5290, 17500)	7600 (5290, 17500)	
Platelet	Mean ± SD	265.82 ± 91.22	279.24 ± 98.53	272.53 ± 93.74	0.8768 ^{MW}
	Median (Min, Max)	257 (105, 544)	253 (169, 565)	255 (105, 565)	
Total Bilirubin	Mean ± SD	0.74 ± 0.51	0.81 ± 0.72	0.78 ± 0.61	0.8904 ^{MW}
	Median (Min, Max)	0.64 (0.18, 2.04)	0.59 (0.23, 2.74)	0.64 (0.18, 2.74)	
Direct Bilirubin	Mean ± SD	0.34 ± 0.26	0.39 ± 0.48	0.37 ± 0.38	0.6917 ^{MW}
	Median (Min, Max)	0.3 (0.03, 0.92)	0.24 (0.1, 1.94)	0.25 (0.03, 1.94)	
Indirect Bilirubin	Mean ± SD	0.41 ± 0.27	0.46 ± 0.31	0.43 ± 0.29	0.5933 ^{MW}
	Median (Min, Max)	0.34 (0.09, 1.12)	0.42 (0.11, 1.3)	0.36 (0.09, 1.3)	
SGOT	Mean ± SD	28.65 ± 14.82	29.41 ± 22.81	29.03 ± 18.95	0.3599 ^{MW}
	Median (Min, Max)	23 (14, 74)	20 (15, 108)	21.5 (14, 108)	
SGPT	Mean ± SD	33.47 ± 24.58	22.47 ± 13.49	27.97 ± 20.31	0.0787 ^{MW}
	Median (Min, Max)	26 (12, 112)	18 (10, 52)	22 (10, 112)	
ALP	Mean ± SD	98.76 ± 31.81	99.29 ± 40.93	99.03 ± 36.1	0.9667 ^t
	Median (Min, Max)	87 (45, 170)	93 (34, 208)	91.5 (34, 208)	
Total Protein	Mean ± SD	7.16 ± 0.45	7.09 ± 0.71	7.13 ± 0.58	0.8491 ^{MW}
	Median (Min, Max)	7.1 (6.5, 8.1)	7.3 (5.1, 7.8)	7.1 (5.1, 8.1)	
Sr Albumin	Mean ± SD	4.18 ± 0.51	4.16 ± 0.52	4.17 ± 0.5	0.9449 ^{MW}
	Median (Min, Max)	4.3 (3.2, 4.8)	4.2 (2.65, 4.8)	4.2 (2.65, 4.8)	
Mean duration of Stay	Mean ± SD	4.47 ± 1.7	4.47 ± 2.15	4.47 ± 1.91	0.8004 ^{MW}
	Median (Min, Max)	4 (3, 8)	4 (3, 11)	4 (3, 11)	

The hematological and biochemical parameters were comparable between the groups. Total leucocyte counts also showed no significant difference ($p = 0.5932$), with means of 8158.82 ± 2520.43 for Group A and 9102.35 ± 3433.19 for Group B. Platelet counts remained similar across both groups ($p = 0.8768$).

Liver function tests, including total, direct, and indirect bilirubin levels, as well as SGOT, SGPT, ALP, and serum protein levels, demonstrated no statistically significant variations between the groups. The mean duration of hospital stay was identical at 4.47 ± 1.91 days ($p = 0.8004$).

Serum protein levels were comparable, with Group A having a mean of 7.16 ± 0.45 g/dL and Group B at 7.09 ± 0.71 g/dL ($p = 0.8491$). Serum albumin levels were also similar ($p = 0.9449$), averaging 4.18 ± 0.51 g/dL in Group A and 4.16 ± 0.52 g/dL in Group B.

5. DISCUSSION

Laparoscopic cholecystectomy is currently considered the gold standard treatment for cholelithiasis, ¹with its incidence drastically on the rise. Concomitantly surgeons are undertaking even more challenging cases. Along with this the biliary anatomy is highly variable, with studies suggesting a variation in approximately 30% of the cases^{3,4}.

These factors contribute to significant challenges in accurately delineating the biliary anatomy during surgery, posing a common difficulty for surgeons performing laparoscopic cholecystectomy. Such anatomical variations and difficulties in identification elevate the risk of serious complications, including bile duct injury and post-operative bile leakage. The use of

ICG dye with NIRF imaging provides a significant guiding tool in the armament of the surgeon while performing a laparoscopic cholecystectomy.

Although various studies have proved the effectiveness of ICG in delineating biliary anatomy, many of them have reported improper visualization due to poor illumination of the biliary structures.(7)

Various factors like liver function, protein and albumin levels, blood supply etc have been implicated in the filtration of the dye from the liver^{7,8}.

In our study the overall identification rates for cystic duct, CHD and CBD was 82.3, 76.4 and 67.7 respectively. These results were comparable with the findings of Vlek et al., in which a systemic review of 19 studies pertaining to the use of ICG in laparoscopic cholecystectomy.⁹ showed similar rates of identification of structures. Although this systemic review compared the various dosage regimens it did not compare the pre operative timings.

Similar studies conducted have concluded the effectiveness of ICG in identification of biliary anatomy and its effectiveness in lap cholecystectomy. Ambe et al, Obonna 2020 et al, Kokudo and Ishizawa, 2012 and other studies have yielded consistent results.^{8,10,11}

Ambe et al., 2019 used 1 hour to 1.5 hrs pre-operative use of ICG, and Obonna 2020 et al. used 45 mins preoperative use of ICG^{10,11}. Both these studies had similar findings.

In our study on further interpreting the results it was observed that Group B showed overall better identification rates. Although between the two groups the identification rates of cystic duct and common bile duct were statistically comparable with identification rates of 76% vs 88% and 64% vs 88% respectively.

However the identification rates for common hepatic duct were significantly higher in group B with identification rates of 47% vs 88% respectively.

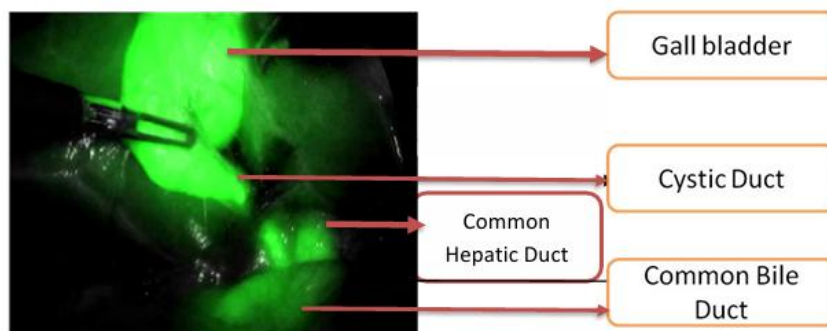


Image -Group B Better Visualization Of Biliary Structures Due To Lesser Background Hepatic Illumination

Correspondingly it was observed that significant liver illumination was observed in Group A with illumination rates of 100% and 41% respectively. Thus suggesting that the dye has not completely filtered out of the hepatic parenchyma.

This remnant illumination of the liver thus hampers the proper visualization of the common hepatic duct. Although the dye is filtered and illuminates the CHD within 3 hours of pre-operative use the background liver illuminations renders it ineffective in proper delineation of biliary anatomy and decreases its practical effectiveness.

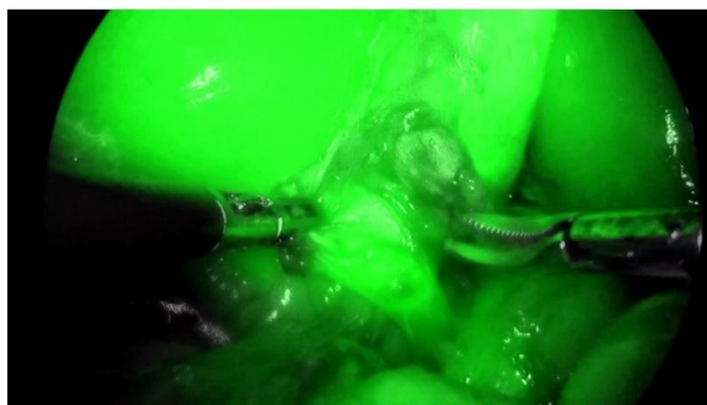


Image-Group A Excessive Hepatic Illumination Hampers Clear Visualization Of Biliary Structures

However in group B after 3 hours the liver illumination drops suggesting that majority of the dye is filtered out of the liver parenchyma. With better identification of biliary structures, likely due to concentration of bile in the biliary tree.

Thus better visualization provides for better surgical safety and can reduce the dreaded complications of bile duct injuries.

These findings were consistent with a systematic review by Boogerd et al. (2017) found twenty- trials with 1057 patients. The bulk of research employed 2.5mg given one hour before imaging. The clinical research findings indicated that the highest ratio of fluorescence between the bile duct and liver was achieved within a time frame of 3-7 hours after administering 5 mg of ICG, and within a time frame of 5-25 hours after administering 10mg of ICG. Up to three hours after administering 5 mg of ICG, the liver exhibited fluorescence that was equal to or greater than the fluorescence of the cystic duct. Similarly, up to five hours after administering 10 mg of ICG, the liver continued to exhibit fluorescence¹²

Zarrinpar et al and Tagaya et al also showed similar findings. It was also observed that at the end of 6 hours the illuminance fades however this was difficult to quantify with the available laparoscopic systems.

We can also postulate that since the biliary anatomy during laparoscopic cholecystectomy is such that liver forms the background in visualization of CHD as compared to cystic duct and Common bile duct, maximum visualization of CHD is hampered by the background liver illuminance.

However various other factors such as liver function, protein levels and presence of dense adhesions also affect the illuminance levels and further studies are required in this domain.

The overall time for surgery and time required to identify the critical view of safety was same in both the groups.

However contrary to our hypothesis one bile duct injury was observed in Group B, for which the exact cause could not be explained.

6. CONCLUSION

The use of Indocyanine green is effective in successfully identifying the extrahepatic biliary structures including cystic duct, common bile duct and common hepatic duct.

Preoperative use of Indocyanine green between 3-6 hours prior to the procedure provides better delineation of the biliary anatomy with significant better delineation of the common hepatic duct and a better illumination ratio between the liver and biliary structures

REFERENCES

- [1] Soper, N. J., Stockmann, P. T., Dunnegan, D. L. & Ashley, S. W. Laparoscopic Cholecystectomy The New 'Gold Standard'? Archives of Surgery 127, 917–923 (1992).
- [2] Kapoor, V. K. Epidemiology of Bile Duct Injury. in Post-cholecystectomy Bile Duct Injury (ed. Kapoor, V. K.) 11–19 (Springer, Singapore, 2020). doi:10.1007/978-981-15-1236-0_2.
- [3] Anatomic variations in intrahepatic bile ducts in a north Indian population | Request PDF. https://www.researchgate.net/publication/23168687_Anatomic_variations_in_intrahepatic_bile_ducts_in_a_north_Indian_population.
- [4] Naeem, M. Q. et al. Prevalence of Different Hepatobiliary Tree Variants on Magnetic Resonance Cholangiopancreatography in Patients Visiting a Tertiary Care Teaching Hospital in Karachi. Cureus 12, e12329.
- [5] A comprehensive predictive scoring method for difficult laparoscopic cholecystectomy - PMC. <https://www.ncbi.nlm.nih.gov/pmc/articles/PMC3996733/>.
- [6] Carroll, B. J. Laparoscopic Cholecystectomy: The American Technique. in Operative Strategies in Laparoscopic Surgery (eds. Phillips, E. H. & Rosenthal, R. J.) 34–38 (Springer, Berlin, Heidelberg, 1995). doi:10.1007/978-3-642-57797-0_7.
- [7] Chen, Y., Liu, G., Wu, Y. & Cai, H. Assessment of liver injury using indocyanine green fluorescence imaging. Annals of Translational Medicine 9, 1167 (2021).
- [8] Kokudo, N. & Ishizawa, T. Clinical Application of Fluorescence Imaging of Liver Cancer Using Indocyanine Green. Liver Cancer 1, 15–21 (2012).
- [9] Vlek, S. L. et al. Biliary tract visualization using near-infrared imaging with indocyanine green during laparoscopic cholecystectomy: results of a systematic review. Surg Endosc 31, 2731–2742 (2017).
- [10] Ambe, P. C., Plambeck, J., Fernandez-Jesberg, V. & Zarras, K. The role of indocyanine green fluoroscopy for intraoperative bile duct visualization during laparoscopic cholecystectomy: an observational cohort study in 70 patients. Patient Safety in Surgery 13, 2 (2019).

- [11] Obonna, G. C. & Obonna, M. C. Role of Indocyanine Green in Laparoscopic Cholecystectomy. *World Journal of Laparoscopic Surgery with DVD* 13, 1–3 (2020).
- [12] Boogerd, L. S. F. et al. The Best Approach for Laparoscopic Fluorescence Cholangiography: Overview of the Literature and Optimization of Dose and Dosing Time. *Surg Innov* 24, 386–396 (2017).
-

