

## CASE REPORT

# Temporary Abdominal Wall Closure in Congenital Diaphragmatic Hernia by Bogota Bag Method

RaviKumar Ramanathan Valkodai\*

Consultant Paediatric Surgeon, G.Kuppusami Naidu Hospital, Nethaji Road, Coimbatore 641037

**How to cite:** Valkodai RR. Temporary abdominal wall closure in congenital diaphragmatic hernia by Bogota bag method. J Neonatal Surg. 2017; 6:80.

This is an open-access article distributed under the terms of the Creative Commons Attribution License, which permits unrestricted use, distribution, and reproduction in any medium, provided the original work is properly cited.

### ABSTRACT

In neonatal congenital diaphragmatic hernia (CDH) repair if the abdomen is closed with tension it poses the problem of abdominal compartment syndrome (ACS). In the index case with ACS, temporary closure of the abdomen was achieved with sterile urobag called the 'Bogota bag technique' with successful complete closure of abdomen after seven days. The other methods of temporary closure of the abdomen are discussed with emphasis on prevention of abdominal compartment syndrome. The ease and simplicity of the technique of urobag utilisation in such situation is outlined in the article.

**Key words:** Congenital Diaphragmatic hernia; Bogota bag; Abdominal compartment syndrome; Vacuum-assisted closure; Delayed facial closure

### INTRODUCTION

Abdominal compartment syndrome (ACS) is a known fatal complication during repair of congenital diaphragmatic hernia. Conventionally, a ventral hernia is created in such situations in the midline of the abdomen with secondary closure. In an earlier case, it resulted in severe adhesions of bowel to the under surface of the skin. The non-availability of vac assisted procedures for ACS made us chose the urobag for temporary abdominal closure, a procedure in vogue in adult trauma surgery called the 'Bogota bag technique'.

### CASE REPORT

A male neonate, one of the twins, with prenatal diagnosis of CDH needed ventilator support in the immediate postnatal period. X-ray chest showed that the child had left diaphragmatic hernia. Total absence of gas in the abdomen suggested that the entire bowel was inside the thorax (Fig. 1a). After five days of ventilation, the child was taken up for surgery. The thorax contained whole small bowel, large bowel including the caecum and appendix,

stomach, left lobe of liver and spleen. After repair of the diaphragmatic defect, they could not be accommodated in the abdominal cavity without producing compartmental syndrome since the abdominal cavity was small. The eviscerated abdominal contents (Fig. 1b) were covered with a sterile urobag which was sutured to the skin margin. A six French feeding tube was kept inside to drain the fluid inside the bag and also to irrigate the bowel twice daily with 10 ml. of Ringer lactate.

The bag was over sewn every day in the nursery itself with progressive reduction of the abdominal contents into the abdominal cavity. An infant feeding tube was kept for irrigation of the abdominal contents and the adhesions of the bowel were minimum.

By the seventh day, the entire eviscerated contents of the abdomen settled in the abdominal cavity without any distress and the abdomen could be comfortably closed. The neonate made good recovery (Fig. 2). Post-operatively, the neonate had regurgitation of feeds due gastro-esophageal reflux for few weeks that slowly subsided with prokinetic drugs

**Correspondence** RaviKumar Ramanathan Valkodai, Consultant Paediatric Surgeon, G.Kuppusami Naidu Hospital, Nethaji Road, Coimbatore 641037, India

E mail: vr.ravikumar@gmail.com

Submitted: 19-06-2017

Conflict of interest: Nil

© 2017, Harris et al

Accepted: 26-09-2017

Source of Support: Nil

and postural feeding. He was asymptomatic and gaining weight on follow up after 3 months.

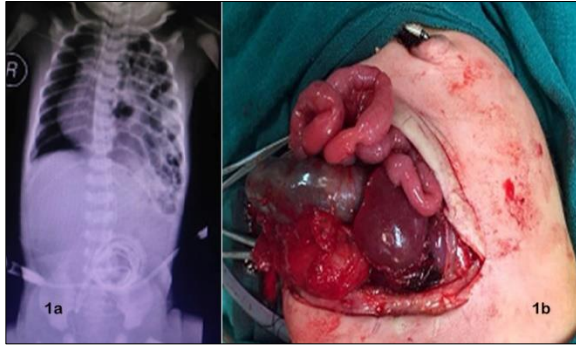


Figure 1: a) Congenital diaphragmatic hernia. b) The eviscerated contents of the abdomen after CDH repair.

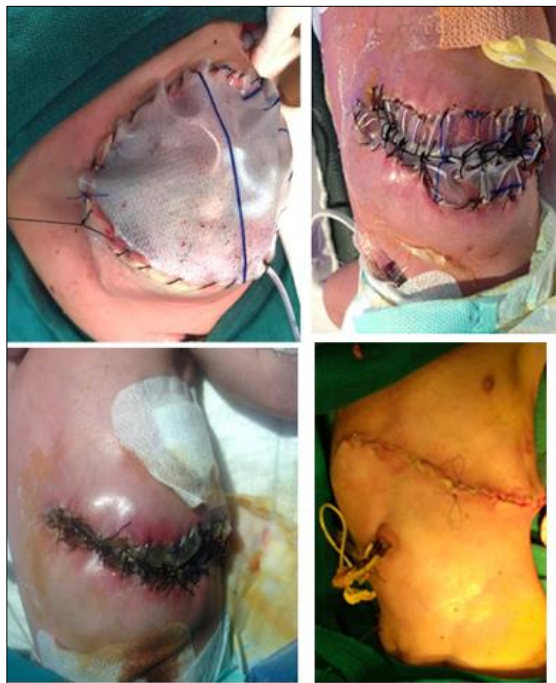

Figure 2: Bogota bag technique of closure of abdominal contents.

## DISCUSSION

ACS is a recognised complication in CDH. In CDH, the abdominal cavity is not well developed due to intra uterine herniation of bowel and viscera into the thorax. Tight closure of the abdomen results in decreased perfusion of every intra-abdominal organ. It decreases severely the splanchnic flow and reduction of venous return with concomitant decrease in cardiac output. The diaphragm gets splinted with decrease in pulmonary compliance with high mortality. Most of the children will need delayed facial closure (DFC) to avoid ACS.

In this neonate, large portion of abdominal viscera could not be accommodated into the abdomen without producing compartment syndrome. In a

study of 349 patients with CDH, 3 (0.8%) were diagnosed with ACS, while 43 patients (12%) had DFC at the time of CDH repair; delayed closure of abdomen with temporary cover was stressed. [1] Different methods of temporary closure of the abdomen have been advocated. Temporary abdominal vacuum-packing (VAC) closure, well known in adult literature has been tried in neonates. [2, 3] In another study 15 neonates in whom the above procedure was tried, there was eighty percent survival with one entero-cutaneous fistula. Silastic prosthesis has been used to widen the abdominal cavity in neonates which allowed slow reduction of the abdominal contents with primary healing. [4, 5] A staged management of giant abdominal wall defects by polyglactin mesh with bed side pleating in adults had 15 % mortality and 8 % fistula rate. [6]

The index neonate could not have been primarily closed without resulting in ACS. A simple sterile urinary bag was sutured to the abdominal skin with daily pleating of the sac in the neonatal nursery with progressive reduction of abdominal contents into the abdomen and ultimate closure (Fig. 2). 'Bogota bag' though doesn't represent a technique for fascial closure, it is simple to perform, safe, and with low cost. It is a therapeutic option for patients with open abdomen, especially if primary closure of the abdomen was not possible without producing ACS. 'Bogota bag' is easily available and much cheaper when compared to VAC. However, the VAC technique is considered efficient, not only because it reduces the tension on the borders of the lesion, but also removes stagnant fluids and debris and acts at the cellular level increasing cell proliferation and division. 'Bogota bag' needs a stent for draining fluids and wash-ups, with higher rates of intestinal adhesion to the abdominal wall. [7] In the neonate cited above, a feeding tube was kept for irrigation of the abdominal contents and the adhesions of the bowel was minimum. The combination of 'Bogota bag' and VAC in severely traumatised adults with ACS has given good results. [8]

## REFERENCES

1. Maxwell D, Baird R, Puligandla P. Abdominal wall closure in neonates after congenital diaphragmatic hernia repair. *J Pediatr Surg.* 2013;48:930-4.
2. Fenton SJ, Dodgion CM, Meyers RL, Nichol PF, Scaife ER. Temporary abdominal vacuum-packing closure in the neonatal intensive care unit. *J Pediatr Surg.* 2007; 42:957-61.
3. Hattori K, Numanoglu A, Cox S. Temporary vacuum-assisted closure of the open abdomen in neonates. *Eur J Pediatr Surg* 2017;18.

4. Michalevitz D, Chaimoff C. Use of a Silastic sheet for widening the abdominal cavity in the surgical treatment of diaphragmatic hernia. *J Pediatr Surg*. 1989; 24:265-6.
5. Kyzer S, Sirota L, Chaimoff C. Abdominal wall closure with a silastic patch after repair of congenital diaphragmatic hernia. *Arch Surg*. 2004; 139:296-8.
6. Jernigan TW, Fabian TC, Croce MA, Moore N, Pritchard FE, Minard G, et al. Staged management of giant abdominal wall defects: acute and long-term results. *Ann Surg* 2003;238:349-57.
7. Ribeiro Junior MA, Barros EA, de Carvalho SM, Nascimento VP, Cruvinel Neto J, Fonseca AZ. Open abdomen in gastrointestinal surgery: Which technique is the best for temporary closure during damage control? *World J Gastrointest Surg* 2016; 8:590-7.
8. Von Räden C, Benninger E, Mayer D, Trentz O, Labler L. Bogota-VAC - A newly modified temporary abdominal closure technique. *Eur J Trauma Emerg Surg* 2008; 34:582.