

Letter to the Editor

© 2024, Gupta et al.

Submitted: 23-09-2023

Accepted: 30-11-2023

License: This work is licensed under a [Creative Commons Attribution 4.0 International License](https://creativecommons.org/licenses/by/4.0/).

DOI: <https://doi.org/10.47338/jns.v13.1258>

Second-look surgery in a patient of malrotation with midgut volvulus

Survesh Kumar Gupta, Anand Pandey,* Rahul Kumar Rai, Nirpex Tyagi

Department of Pediatric Surgery, King George's Medical University, Lucknow 226003, UP, India

Correspondence*: Dr. Anand Pandey, Department of Pediatric Surgery, King George's Medical University, Lucknow 226003, UP, India. **E-mail**: dranand27@rediffmail.com

DEAR SIR

A 4-day-old male neonate was referred to us with complaints of sudden onset of bilious vomiting and bleeding per rectum for a day. We clinically suspected malrotation with midgut volvulus and bowel strangulation. The X-ray abdomen of the patient revealed a ground glass appearance. At laparotomy, the whole of the small bowel from 5 cm beyond the duodenojejunal (DJ) junction to the ileocecal (IC) junction was dusky (Fig. 1a,b). There were two turns

of midgut volvulus. The derotation of the bowel was performed, and the abdomen was closed. He was re-explored after 48 hours. We noted that the color changes were now limited to a mid-ileal segment of about 10 cm. The color of the remaining bowel had become normal (Fig. 1b). After resecting the non-viable segment, ileo-ileal anastomosis (Fig. 1c) and Ladd's procedure was performed. The postoperative period was uneventful. As of now, the baby is healthy and doing fine.

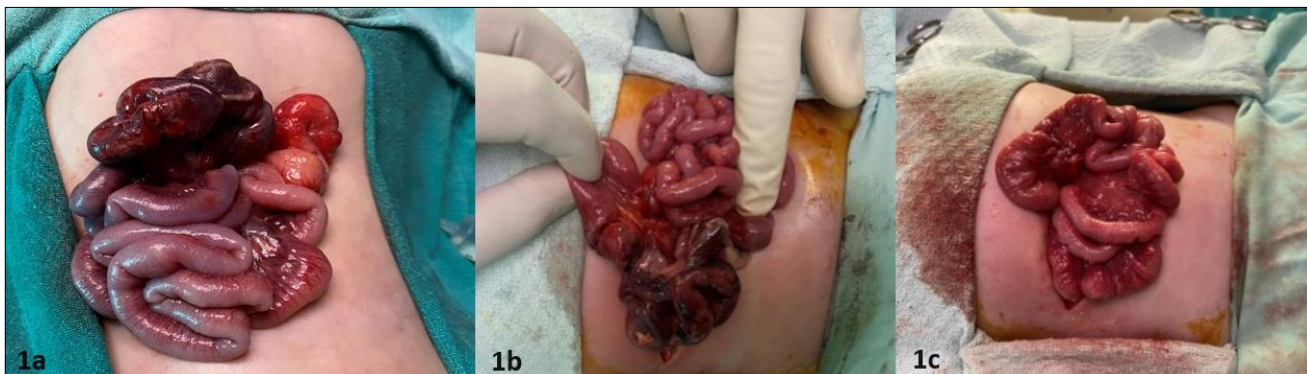


Figure 1: a) Intraoperative appearance after the initial laparotomy. Most of the bowel appears dusky and the line of demarcation is not clear. b) The bowel condition is grossly improved after 48 hours on a second look inspection. Only one gangrenous mid-ileal segment is visible. c) Bowel after resection of the gangrenous segment and ileal anastomosis

A midgut volvulus associated with malrotation is a surgical emergency. [1] It can be suspected with sudden onset of bilious vomiting in a neonate with bleeding per rectum and a gasless abdomen on x-rays, as found in the index case. Second-look surgery is a concept mostly used in neonates of necrotizing enterocolitis (NEC). Here instead of performing extensive resection of the gangrenous bowel in the first surgery, laparotomy is performed the second time after about 48 hours from the first surgery. It is based on the fact that demarcation of bowel viability is not always possible during the first laparotomy. [2]

If exploratory laparotomy reveals extensive gangrenous or dusky bowel, we may not be able to decide the extent of resection. If extensive resection is

performed during the laparotomy, the patient may end up with short bowel syndrome. In such a scenario, the role of second-look surgery becomes imperative. [3] However, reports of its use in midgut volvulus with doubtful viability of bowel are limited. [3-5] In our patient, we did not perform a bowel resection as the bowel was dusky but definite margins for resection were not present; however, in the case of well-set gangrene, it would be better to resect it to avoid the possibility of sepsis in the neonate. The remaining bowel may be clipped to avoid peritoneal contamination. Second-look surgery may then be undertaken at an appropriate time.

To conclude, it is crucial to have a strong suspicion and perform an urgent laparotomy when there is a

suspicion of bowel strangulation accompanied by midgut volvulus in malrotation. When dealing with doubtful bowel viability, a cautious approach to second-look surgery may lead to a successful outcome.

Acknowledgments: Nil.

Conflict of Interest: None declared

REFERENCES

1. Coste AH, Anand S, Nada H, Ahmad H (2022) Midgut Volvulus. [Updated 2022 Sep 12]. In: StatPearls [Internet]. Treasure Island (FL): StatPearls Publishing. Available from: <https://www.ncbi.nlm.nih.gov/books/NBK441962/>
2. Tan YW, Merchant J, Sharma V, Davies B, Singh S, Stewart R, More B (2015) Extensive Necrotising Enterocolitis: Objective Evaluation of the Role of Second-Look Laparotomy in Bowel Salvage and Survival. *World J Surg.* 39:3016-22. doi: 10.1007/s00268-015-3203-5
3. Kulkarni V, Khedkar K, Ramteke H, Lamture Y, Nagtode T, Giri A (2022) Importance of Second-Look Surgery in a Newborn Presenting With Early Malrotation. *Cureus.* 2022 14: e26551. doi: 10.7759/cureus.26551
4. Jan IA, Ziaullah M, Obaid LO, Hassan MA, Shehhi MA (2018) Planned Second look laparotomy in neonatal volvulus - A safe approach for bowel salvage. *Pak J Med Sci.* 34:508-510. doi: 10.12669/pjms.342.14473
5. Hoffman MA, Johnson CL, Moore T, Pearl RH (1992) Management of catastrophic neonatal midgut volvulus with a silo and second-look laparotomy. *J Pediatr Surg.* 27:1336-9. doi: 10.1016/0022-3468(92)90291-e.

Source of Support: Nil

Consent to Publication: Author(s) declared taking informed written consent for the publication of clinical photographs/material (if any used), from the legal guardian of the patient with an understanding that every effort will be made to conceal the identity of the patient, however it cannot be guaranteed.

Author Contributions: Author(s) declared to fulfil authorship criteria as devised by ICMJE and approved the final version.