

Case Series

© 2023 Klyuev et al

Submitted: 30-05-2023

Accepted: 18-07-2023

License: This work is licensed under a [Creative Commons Attribution 4.0 International License](https://creativecommons.org/licenses/by/4.0/).

DOI: <https://doi.org/10.47338/jns.v12.1224>

Neonatal gastric perforation in Twins: Two distinct cases

Sergey Alexandrovich Klyuev, Sergey Yurievich Gorodkov, Igor Vladimirovich Goremykin, Vyacheslav Germanovich Masevkin

Department of Pediatric Surgery, Saratov State Medical University, Saratov, Russian Federation

Correspondence*: Sergey Alexandrovich Klyuev, Department of Pediatric Surgery, Saratov State Medical University, Saratov, Russian Federation. **E-mail**: proklyuev@gmail.com

KEYWORDS

Neonate,
Stomach perforation,
Necrotizing enterocolitis,
Nasogastric tube

ABSTRACT

Background: Neonatal gastric perforation (NGP) is an uncommon but fatal condition. The exact cause of NGP remains unclear, although some cases have been linked to medical interventions. NGP is rarely reported in twins.

Case Presentation: Herein we report two cases of gastric perforation in twins. The first baby was one of the 34-week preterm twins that developed abdominal distension and respiratory distress on the third day of life. While the other baby was one of the 32-week preterm twins that too developed abdominal distension and respiratory distress. Both had gastric perforations that needed surgical repair. One baby died of sepsis while the other neonate had a stormy postoperative course, which was managed with meticulous monitoring and multidisciplinary management, and discharged in good clinical condition.

Conclusion: Clinical cases demonstrate that successful management of NGP requires a multidisciplinary approach, including timely surgical intervention, meticulous postoperative care, and close monitoring of complications.

INTRODUCTION

Neonatal gastric perforation (NGP), although rare, accounts for approximately 7% of all gastrointestinal perforations in this age group. [1,2] The exact cause of this condition is not fully understood, the reported causes include iatrogenic gastric perforation with nasogastric tube insertion or barotrauma, a congenital muscular defect of the stomach, a combination of local ischemia in the stomach wall, and high gastric acidity, and secondary to gastric outlet obstructions. [1-9]. It is rarely reported in preterm twins. Herein, we report two cases of gastric perforation in preterm twins and describe the challenges faced in the management.

CASE SERIES

CASE 1: A second preterm female twin was born at 34 gestational weeks (GW). On the third day of life, the infant exhibited sudden abdominal distension and respiratory distress. Due to the family residing in a remote rural area and the domestic labor commitments, the baby was brought to the hospital by the grandmother on the fourth day. The neonate weighed 1300g upon admission and was immediately transferred to the intensive care unit (ICU).

Physical examination revealed mottled skin, depressed reflexes, and a distended abdomen. The heart rate was 160-166 beats per minute, blood pressure - 70/42 mm Hg, and respiratory rate - 42-48 breaths per minute. The laboratory findings indicated a white blood cell count of $2.93 \times 10^9/L$ with 83.7% neutrophils and thrombocytopenia $86.2 \times 10^9/L$. The patient was also identified to have hyponatremia, with a serum sodium level of 120 mmol/L, and metabolic acidosis. An abdominal X-ray revealed the presence of free gas in the abdominal cavity and ultrasound imaging showed the presence of free fluid in the pelvic cavity. Intra-abdominal pressure was approximately 25 cm H₂O, as measured by a catheter in the urinary bladder.

To relieve gastric distension, a 6 Fr nasogastric (NG) tube was inserted for gastric decompression without any technical difficulties. Primary peritoneal drainage was performed that drained 30ml of yellowish serum with fibrin and a significant amount of gas. Following that, the patient's hemodynamic state improved a bit. Inotropic support started and correction of fluid-electrolyte balance was done.

After hemodynamic stabilization, the patient underwent exploratory laparotomy that showed yellow

fibrin flakes covering intestinal loops (Fig. 1A). The exploration of the stomach revealed a perforation in the pre-pyloric region, with the NG tube protruding through it (Fig. 1B). The origin of the stomach wall perforation and its relationship to the presence of the NG tube as the initial cause remained controversial. The perforation was promptly repaired.

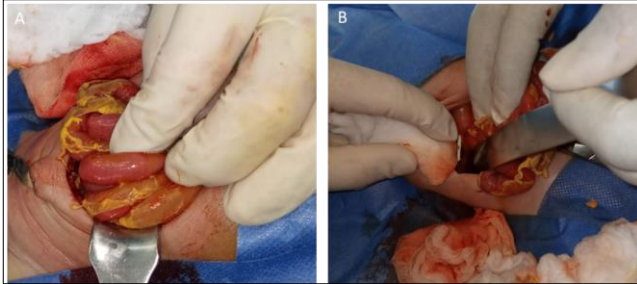


Figure 1: Yellow fibrin flakes covering intestinal loops; B) a perforation in the pre-pyloric region with the NG tube protruding through it.

Despite surgical intervention and meticulous postoperative care, the patient continued to deteriorate and died on the first postoperative day. At that moment, the first twin is alive and in good general health.

CASE 2: A set of dichorionic diamniotic female twins was delivered prematurely at 32 GW through a cesarean section. The mother, aged 36, had previously worked in a chemical plant. The first pregnancy is through in vitro fertilization. The second twin suffered perinatal central nervous system damage and passed away shortly after birth.

Due to the sudden development of abdominal distension and respiratory distress syndrome, the first twin was transferred to the ICU and placed on continuous positive airway pressure (CPAP). Free gas was detected via abdominal X-rays. The patient had thrombocytopenia indicating an advancing NEC. The patient was then given medical preoperative preparation and underwent primary peritoneal draining. Empirical antibacterial therapy was initiated.

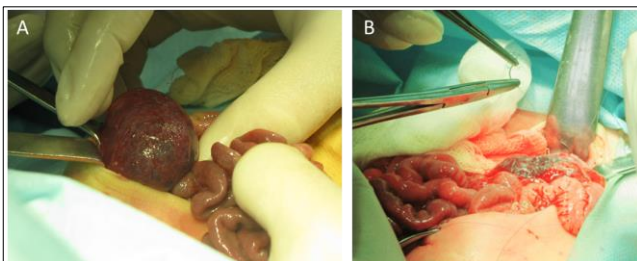


Figure 2: A) An extensive intramural rupture along the lesser curvature of the stomach, from the cardiac region to the initial portion of the duodenum. B) repair is in progress.

Intraoperatively, an extensive intramural rupture along the lesser curvature of the stomach was identified, extending from the cardiac region to the

beginning of the duodenum (Fig. 2). The stomach was repaired.

Postoperatively, the baby required multiple blood component transfusions due to ongoing hemorrhagic complications. Thrombocytopenia was observed and progressively worsened and manifested as a hemorrhagic rash when the platelet count reached $48 \times 10^9/L$, necessitating consultation with a hematologist. Thrombocytopenia was likely a result of the septic process, and low-dose hormonal therapy with prednisolone was initiated. Platelet concentrate transfusions were also administered to manage the thrombocytopenia. Enteral feeding was gradually reintroduced, starting with saline solution and then with formula feed, while closely monitoring the baby's response. With appropriate medical care and multidisciplinary support, the baby showed signs of improvement, including the resolution of abdominal distension, improvement in respiratory and hemodynamic parameters shortly after the surgical procedure, and a reduction in coagulopathy later. After a postoperative period of 18 days, the baby was discharged from the hospital. No gastrointestinal issues have been observed in the long-term follow-up.

DISCUSSION

The origins of Neonatal gastric perforation (NGP) have been debated for many years, although recent research points to spontaneous stomach perforation as being more frequent in newborns than iatrogenic perforation. Despite the rarity of iatrogenic gastric perforation, forceful bag-mask ventilation and perforation brought on by the insertion of an orogastric or nasogastric tube may have been linked. [5] According to our hypothesis, NGP usually affects newborns who have a predisposition, like an underdeveloped stomach wall. It is unclear in the first case whether the placement of the nasogastric tube itself contributed to the perforation or if there was a pre-existing condition that caused both the stomach perforation and the subsequent displacement of the NG tube.

Excessive gastric distension has also been mentioned as a possible iatrogenic cause. [9, 10] This condition might be brought on by improper tracheal intubation or the presence of a tracheo-esophageal fistula. However, in the second instance, the use of CPAP as the primary cause of NGP is still debatable. It is crucial that newborns' stomach walls can exhibit signs of weakness or immaturity, making them more susceptible to rupture during medical procedures.

The occurrence of NGP in premature newborns presents significant challenges in terms of diagnosis and management. It is rarely reported in twins. It is essential to identify the disease promptly and distinguish it from other gastrointestinal perforations in newborns. The most frequent diseases that should

be taken into account when making a differential diagnosis of NGP are NEC and SIP. [9] Although preterm neonates and low-birth-weight neonates make up the majority of patients with these disorders [2], they may display slightly different clinical patterns.

NGP commonly happens between the ages of two and seven days. [1, 2] In our cases, the median age at which symptoms first appeared was about three days. SIP appears to occur more frequently after the second week of delivery, although NEC symptoms normally appear later, commonly after the first week of birth. [8] NGP is associated with several clinical symptoms, which are common for all neonatal gastrointestinal perforations [1], including abdominal distension, feeding intolerance, poor activity, respiratory distress, and abdominal erythema. However, one notable difference in the clinical presentation of NGP compared to NEC and SIP is the presence of sudden shock symptoms, which are more frequently observed in NGP cases. In contrast, the signs of shock in NEC and SIP tend to appear gradually in the advanced stages.

In NGP, the development of sudden shock can be attributed to a component of combined pathogenesis, specifically intra-abdominal hypertension (IAH). [10] In both of the reported cases, there was a rapid increase in intra-abdominal pressure. In NEC, IAH typically develops progressively, whereas in SIP it is not as common or prominent in the initial stages. The presence of sudden shock, coupled with the development of IAH with respiratory distress, distinguishes NGP from NEC and SIP.

Coagulopathy is a secondary complication that can develop in all of the mentioned conditions and often persists as a sign of sepsis in these cases. However, it is worth noting that thrombocytopenia is commonly reported specifically in neonates with stomach rupture. [5, 7] Additionally, as seen in the second

case, thrombocytopenia tends to manifest earlier and last longer following surgery in this situation. This clinical fact may distinguish NGP from the coagulopathy observed in NEC and SIP.

NGP is a life-threatening condition with the reported overall survival rate is approximately 70.3%. [7] Several retrospective studies [5,7] have identified three independent risk factors associated with mortality in NGP cases: shock, serum lactic acid levels above 2.5 mmol/L, and thrombocytopenia.

The successful management of NGP requires a multidisciplinary approach. While the timing of surgical intervention is crucial, conservative support also plays a significant role in improving outcomes. The reported clinical cases, along with other sources, highlight the importance of timely surgical intervention, meticulous postoperative care, and close monitoring of complications such as sepsis and thrombocytopenia.

CONCLUSION

Neonatal gastric perforation is a challenging condition and is rarely found in preterm twins. A comprehensive and coordinated approach, involving both surgical intervention and intensive care, is necessary to optimize the chances of survival in neonates with NGP. This includes timely surgical intervention, attentive postoperative care, and vigilant monitoring for complications

Acknowledgements: Nil

Conflict of Interest: None.

Source of Support: Nil

Consent to Publication: Author(s) declared taking informed written consent for the publication of clinical photographs/material (if any used), from the legal guardian of the patient with an understanding that every effort will be made to conceal the identity of the patient, however it cannot be guaranteed.

Author Contributions: Author(s) declared to fulfil authorship criteria as devised by ICMJE and approved the final version.

REFERENCES

1. Kim E. Gastric perforation in a newborn. *J Pediatr Surg Case Rep.* 2019; 43:87-89. Available from: <https://doi.org/10.1016/j.epsc.2019.02.009>.
2. Huerta CT, Perez EA. Diagnosis and management of neonatal gastric perforation: a narrative review. *Dig Med Res.* 2022; 5:27. Available from: <https://doi.org/10.21037/dmr-21-105>.
3. Parasuraman D, Roy R, Mitchell S. Iatrogenic gastric perforation in a preterm infant: clinical presentation and radiological indicators. *Internet J Pediatr Neonatol.* 2006; 7(1).
4. Yang T, Huang Y, Li J. Neonatal gastric perforation: case series and literature review. *World J Surg.* 2018; 42:2668-73.
5. Sato M, Hamada Y, Kohno M, Ise K, Uchida K, Ogata H, et al. Neonatal gastrointestinal perforation in Japan: a nationwide survey. *Pediatr Surg Int.* 2017; 33:33-41. Available from: <https://doi.org/10.1007/s00383-016-3985-z>.
6. Yang CY, Lien R, Fu RH, Chu SM, Hsu JF, Lai JY, et al. Prognostic factors and concomitant anomalies in neonatal gastric perforation. *J Pediatr Surg.* 2015 Aug;50(8):1278-82. Available from: <https://doi.org/10.1016/j.jpedsurg.2015.04.007>.
7. Huang Y, Lu Q, Peng N, Wang L, Song Y, Zhong Q, et al. Risk Factors for Mortality in Neonatal Gastric Perforation: A Retrospective Cohort Study. *Front Pediatr.* 2021 May 13;9:652139. Available from: <https://doi.org/10.3389/fped.2021.652139>.
8. Korai T, Kouchi K, Takenouchi A, Matsuoka A, Yabe K, Nakata C. Recurrent intestinal ischemia following surgery for gastric and duodenal perforations: a case

- report. Surg Case Rep. 2019; 5:124. Available from: <https://doi.org/10.1186/s40792-019-0683-9>.
9. Klyuev SA, Goremykin IV, Masevkin VG, Gorodkov SY, Nikolaev AV, Shintaev TK, et al. Acute gastric dilation with necrosis: case report and literature review. J Clin Trials Exp Investig. 2022; 1:32-40. Available from: <https://doi.org/10.5281/zenodo.7007932>.
 10. Morozov DA, Morozova OL, Klyuev SA, Budnik IA, Maltseva LD, Morozov KD. Intra-abdominal hypertension in children. Surg News. Ministry of Health of the Byelorussia Republic 2017; 25:621-32. Available from: [https://doi: 10.18484/2305-0047.2017.6.621](https://doi:10.18484/2305-0047.2017.6.621)
 11. Gordon PV. Understanding intestinal vulnerability to perforation in the extremely low birth weight infant. Pediatr Res. 2009; 65:138-44. Available from: <https://doi.org/10.1203/PDR.0b013e31818c7920>.
-