

Original Article

© 2022 Assouto et al.

Submitted: 19-03-2022

Accepted: 26-07-2022

License: This work is licensed under a [Creative Commons Attribution 4.0 International License](https://creativecommons.org/licenses/by/4.0/).

DOI: <https://doi.org/10.47338/jns.v11.1077>

Dismal outcome of gastroschisis in a resource-limited country in West Africa: Relevant issues and what to expect?

Cedric Bignon Ulrich Assouto,¹ Amoussou Sedjro Clotaire Romeo Houegban,^{1*} Beaudelaire Romulus Assan,¹ Nicole Enianloko Tchiakpe,² Michel Armand Fiogbe,³ Antoine Seraphin Gbenou,¹

1 Department of Pediatric Surgery, Mother and Child Teaching Hospital Lagune, University of Abomey-Calavi, Benin. 2 Department of Pediatrics, Neonatology Unit, Mother and Child Teaching Hospital Lagune, University of Abomey-Calavi, Benin. 3 Department of Pediatric Surgery, National University Hospital Center "Hubert Koutoukou Maga", University of Abomey-Calavi, Benin

Correspondence*: Amoussou Sedjro Clotaire Romeo Houegban, MD, Department of Pediatric Surgery, University of Abomey-Calavi, Benin. **E-mail:** huegbanromeo@gmail.com

KEYWORDS

Gastroschisis,
Antenatal Diagnosis,
Outcome,
Mortality,
Developing country

ABSTRACT

Background: Gastroschisis often has a fatal outcome in developing countries. Its outcome is taken as an indicator of the level of healthcare in a particular healthcare facility. The aim was to study the outcome of the management of gastroschisis and to identify the main challenges of its treatment in a country with limited resources.

Methods: This is a prospective and descriptive study conducted over a period of 4 years (2016-2020). It included all the neonates admitted to the two referral hospitals of our country with the diagnosis of gastroschisis. Each of the university hospitals had a neonatology unit. Parenteral nutrition and assisted ventilation were not available.

Results: Twenty patients were admitted to our hospitals with an annual frequency of five cases. The sex ratio (M:F) was 1.5. Only one of the 20 mothers (5%) of the patients had an antenatal diagnosis and was the only one born in a university hospital. The remaining (19-95%) were referred to a university hospital after their birth. None of the 20 patients had received parenteral nutrition. Surgically, seven babies (35%) had benefited from the placement of a silo with progressive reduction of the bowels. The mortality of gastroschisis was 100% and the average life span of the patients was 4.5 days [1-20 days].

Conclusion: It is important to act appropriately on the whole chain of management of gastroschisis from antenatal diagnosis to treatment so that this pathology is no longer fatal for newborns in countries with limited resources.

INTRODUCTION

Gastroschisis is characterized by a right para-umbilical defect through which the contents of the abdomen extrude. Through this defect, the small intestines and the colon are most often externalized and more rarely the liver and the stomach. [1] In recent years, there has been considerable progress in the management of this anomaly in developed countries, but the situation is still dismal in sub-Saharan Africa where mortality remains high. In fact, this management is so challenging in Africa that the disease has been identified as an indicator of the level of health in pediatrics. [2] Our country is a resource-constrained country and no study had yet been conducted on this congenital abdominal wall defect.

The aim of this work was to study the outcome of the management of gastroschisis and to identify the main

challenges of its treatment in a country with limited resources.

METHODS

It was a prospective descriptive study conducted over a period of four years (2016 - 2020). Our study took place in the pediatric surgery and neonatology departments of the two pediatric referral hospitals in our country. They were the only teaching hospitals with pediatric surgery and neonatology units in our country.

The National Ethics Committee approved the study.

The inclusion criteria were neonates (1-28 days) with a clinical diagnosis of gastroschisis. Without neonatal resuscitation or intensive care unit, all neonates were hospitalized in neonatology.

For each patient, the following variables were studied: sex, gestational age, birth weight, consultation time, antenatal diagnosis, referral modalities, clinical signs at admission, treatment, and outcome.

Parenteral nutrition and assisted ventilation were not available.

The Lefort classification was used to specify the type of gastroschisis (Table 1).

Table 1: Classification of Lefort for gastroschisis

Type	Aspect	Colon / Small Bowel Length	Atresia	Membrane
Type 1	Good	Sufficient	Absent	
Type 2	Poorly vascularized	Sufficient	Absent	Inflamed
Type 3	Poorly vascularized	Reduced	Present: colon with or without small bowel	Inflamed
Type 4		Quasi total necrosis of the intestine		

Several pieces of equipment were not available in our centers. The main equipment involved is listed in Table 2.

Table 2: Unavailable facilities

Facilities	Department
Infrastructures	NCIU
Human resources	Qualified personnel in neonatal resuscitation (nurses, physicians, pediatricians, etc...)
Neonatal resuscitation equipment	Parenteral nutrition solutions, non-availability of material for taking a central venous route (catheters, implantable venous device, mobile ultrasound, endoscopes)

Data processing was performed using SPSS statistics 25.0 software. In the analytical part, the non-parametric test of Kruskal-Wallis or Mann-Whitney U adapted for the continuous variables was used to compare the medians while for the qualitative variables it was a question of chi-square or Fisher exact tests with a threshold of statistical significance $p < 0.05$. The correlation analysis between some quantitative variables was performed using Spearman's correlation coefficient.

Our protocol for the management of gastroschisis

Patients with the antenatal diagnosis were recommended for vaginal delivery or C-section in case of obstetric reasons, in presence of a Pediatric Surgeon. Upon admission, these infants were placed on a warming table in the neonatal unit. A nasogastric tube was inserted. A peripheral venous route was established. IV fluid was given, and

prophylactic antibiotics started (cefotaxime 150 mg/kg per day in three doses; metronidazole 30 mg/kg per day in two doses).

After gentle cleaning of the intestines with warm normal saline, the eviscerated intestines were covered initially with saline-soaked dressing; followed by either primary reduction and closure of the defect or placement of eviscerated bowel in a feminidom (female condom) (Fig.1) or Alexis wound retractor (Fig.2) was used to initiate a gradual reduction of the intestines into the abdomen. After complete reduction of these loops intra-abdominally, the para-umbilical defect is closed.

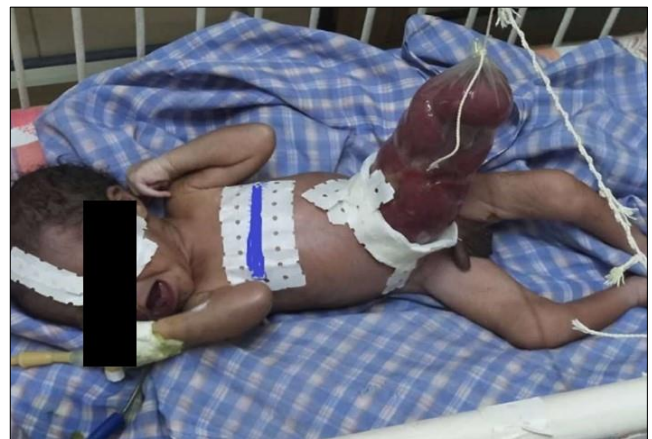

Figure 1: Female condom used as a silo.

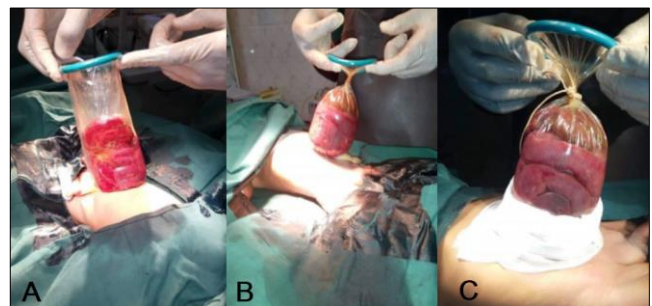


Figure 2: Stages of the use of Alexis wound retractor in the operating room. The progressive reintegration was done every day by accentuating the twists and by blocking with knots from proximal to distal A. After careful examination of the bowel to rule out further intestinal malformations, Alexis wound retractor was inserted perpendicularly into the abdominal cavity. B. Then, the proximal ring of the device was closed by making several turns of the spiral. C. A knot was made at the proximal part of the device and the lower part was protected by a strip of velpeau reinforced with a plaster.

Breast milk feeding (given by spoon) was started quite early (often one day after the beginning of the reintegration of the intestines) with monitoring of the intestinal transit. Evacuating rectal washouts were also performed to facilitate bowel transit.

RESULTS

Demography

We recorded 20 cases of gastroschisis out of 19,525 neonates admitted, i.e., a hospital frequency of 0.10%

or about 10 cases per 10,000 births with an average of 5 cases per year. Nineteen neonates (95%) were referred with a mean age of 16 hours [2 - 30 hours]. The sex ratio was 1.5 (12 male and 8 female neonates). The mean term of pregnancy was 36 weeks, 4 days [32 - 40 weeks of amenorrhea].

Four mothers (20%) had undergone at least one prenatal ultrasound; of these, in only one mother an antenatal diagnosis of gastroschisis was made on an antenatal scan. The diagnosis was made during an ultrasound performed at 26 weeks of amenorrhea by an obstetrician. We could not specify the type of health worker who performed antenatal scans on the other 3 mothers.

All patients were born vaginally except for the one patient who had an antenatal diagnosis. The mean birth weight of the neonates was 2.265 kilograms \pm 0.612 [1.520-3.300 kilograms]. Type I gastroschisis according to the Lefort classification was found in 75% of cases. One newborn (5%) had a visible external malformation such as arthrogryposis.

On admissions, six cases had sepsis, one case had hypovolemia, and three cases had hypothermia. One neonate had both hypovolemia and sepsis, and another had hypothermia and sepsis. The remaining eight neonates were in relatively better condition.

Management

All patients had been treated according to the protocol described above.

After initial rapid optimization, seven neonates (35%) underwent placement of a silo with progressive reintegration of the intestines, and three (15%) had undergone immediate closure under general anesthesia. Table 3 shows the details of the pattern of the treatment.

Table 3: Pattern of treatments used

Pattern of treatments used	Frequency	%
Immediate surgical closure	3	15,0
Surgical Silo	7	35,0
Feminidom (female condom)	4	20,0
Saline dressing	5	25,0
Partial reintegration of the loops and placement of a blood bag	1	5,0
Total	20	100,0

Outcome

The complications encountered included: five cases of surgical site infection, two cases of intestinal

obstruction, one case of abdominal compartment syndrome, one case of hematemesis, and 15 cases of malnutrition. Unfortunately, none of the patients survived. All the patients who received surgical silo placement with gradual reintegration died before the complete bowel reintegration. The average life expectancy of the patients was 4.5 days [1-20 days].

DISCUSSION

Epidemiological aspects

Our incidence of 5 cases of gastroschisis per year is similar to that found in South Africa (4 cases) [3] and Brazil (4 cases). [4] Other authors have reported a higher incidence like the reported incidence in the US is 14.3 cases/year [5] and in Singapore, it is 12 cases/year. [6] This data reflects that gastroschisis is uncommon in our country. Although our 2 collecting centers are the only university hospitals with pediatric surgeons, this prevalence seems to be lower than the actual prevalence. Due to socio-cultural and economic considerations, a group of patients is not referred and die early before referral. This represents the first challenge. Indeed, the real prevalence is not known, because not all patients manage to consult a pediatric surgeon, making in-depth epidemiological and clinical studies difficult.

Diagnostic aspects

Antenatal diagnosis was made in only one case out of 20, i.e., in 5% of the cases. Overall, there is a very low proportion of getting an antenatal ultrasound during pregnancy that too with very minimal yield. The random availability of ultrasound machines in peripheral hospitals and the absence of qualified personnel to perform these ultrasounds could explain it. In addition, the high cost of ultrasound for the population living in a context of lack of social medical insurance would be an additional factor.

Antenatal diagnosis of gastroschisis allows for a better organization of neonatal care, including in utero transfer and neonatal medical and surgical management. [7] This has greatly improved the prognosis in developed countries. However, in our countries, due to the absence of an antenatal diagnosis, the planning of neonatal care poses serious problems. They do not benefit from either the covering of a warming bag or from adequate medical transport. The neonates are brought by the parents themselves, with their own means of transport, and covered by used loincloths in most cases.

Mode of delivery and term of pregnancy

The only mother with a prenatal diagnosis for her fetus delivered by cesarean section at 35 weeks of amenorrhea. All other mothers in our study had delivered by vaginal delivery.

It should be noted that the systematic practice of cesarean section in case of gastroschisis in the fetus is currently a topic of controversy. In fact, some studies show that the fact of delivering by cesarean section or vaginal delivery has no impact on the outcome of the newborn. [8,9] As for the ideal mode of delivery, studies have shown an advantage of premature delivery (before the 34th week), particularly by cesarean section. This option would decrease the rate of complications during hospitalization and would reduce the length of stay of the newborn suffering from gastroschisis in the hospital. [10,11] However, the latest studies prove that there was no significant difference between the two options and that one should simply wait for the mother to go into labor and deliver her by vaginal delivery. [12]

However, it is not the mode and term of delivery that are the main challenges in our context. The promotion of antenatal diagnosis by the referring gynecologist or midwife should be the priority because it implies a referral in utero to specialized centers.

Therapeutic aspects

Neonatal resuscitation

The management of gastroschisis requires optimal preoperative condition in a neonatal intensive care unit (NICU): keeping the baby in the left lateral position to avoid angulation of the intestines which could lead to ischemia, insertion of a nasogastric tube, preservation of normothermia, prevention or treatment of infections, correction of fluid-electrolytic imbalances, and parenteral nutrition through a central venous route. [13]

In our context, multiple deficiencies were noted. These were the absence of NICU, the absence of neonatal resuscitation equipment, and the lack of qualified personnel in neonatal resuscitation. The main therapeutic challenge here remains the absence of parenteral nutrition as well as the non-availability of facilities for establishing a central venous route (catheters, implantable venous devices, mobile ultrasound, endoscopes). Indeed, none of our patients had received parenteral nutrition. However, recent studies have clearly demonstrated the benefit of parenteral nutrition in these patients.

Contrarily, the developed countries have properly trained staff, with the availability of various central catheters that can be inserted via a peripheral approach and central veins. In addition, the availability of specialized equipment such as ultrasound aids in efficient venous access. [14]

In the developed countries the prognosis has improved as to the improvements in perioperative care, anesthesia management, and ICU facilities; the survival rate approaching 100% while it is still bleak

in our countries. In an international survey, only 19% of tertiary pediatric surgical centers in these countries had access to parenteral nutrition. [15] The shorter reference life of neonatal parenteral nutrition compared to that of adults purchased by manufacturing companies in these countries adds to the complexity in terms of transport and the risk of becoming waste.

Type of surgical treatment

Approximately one-third (7) of the babies received surgical silo placement (Alexis wound retractors) with gradual reintegration of the loops. The other method of covering the bowels was the female condom in 4 patients. Due to the unavailability of the silo, we are trying other alternatives which are obviously not effective considering the high mortality rate.

The optimal method of reduction and closure of gastroschisis remains controversial. The two most used methods are primary closure under general anesthesia in the operating room or serial reductions using a preformed silo over several days followed by the closure at the bedside or in the operating room. [16] A randomized controlled trial demonstrated that primary closure with the preformed silo reported a lower ventilation requirement. [17] A meta-analysis comparing immediate closure with all staged closure methods also reported a need for fewer days of ventilation ($p < 0.0001$), reduced time to first feeding ($p = 0.04$), and a lower infection rate ($p = 0.03$) in the latter group. [18] Subsequently, a systematic review and meta-analysis comparing the preformed silo with all alternative strategies reported low ventilation use in the former group. Indeed, many neonates in the silo group did not require ventilation. [16]

These findings are consistent with the low risk of abdominal compartment syndrome in the use of the preformed silo. The increased cardiorespiratory support required after primary closure can usually be provided in a setting where a neonatal intensive care unit (NICU) is available. This is often unavailable in developing countries. [15] In addition, edematous and entangled bowels resulting from late presentations with plastic peritonitis in our countries may predispose to the more severe abdominal compartment syndrome in case of primary closure. This leads us to conclude that the preformed silo may result in better outcomes in our countries. [19]

The reasons for the limited use of silos in our country include the lack of availability, the financial burdens associated with its acquisition [15], and the non-prioritization of this material in the basic equipment of pediatric surgical services. This constitutes another major challenge.

It is estimated that 63-79% of infants with gastroschisis in low- and middle-income countries

undergo general anesthesia for bowel reduction and abdominal wall closure. [15] Neonatal anesthesia can be life-threatening in this setting due to a lack of specialized training, and resources, and the high Association of Anaesthesiologists (ASA) Score of the neonate at the time of surgery due to limited pre-hospital management. [20]

Mortality rate

None of the newborns in our study survived with a 100 % mortality. This alarming mortality rate is most often encountered in low- and middle-income countries. This was the case with Ameh [21] who recorded 10 out of 14 deaths, Ade-Ajayi et al [3] who recorded 5 out of 5 deaths in Nigeria, and Wesonga et al [22] in Uganda who found a 98% mortality rate.

On the other hand, in developed centers, few newborns die from gastroschisis. Thus, no death was noted in the series of Payne [23] in the USA on 155 patients. Other authors have had few deaths: 12 deaths out of 302 in the series by Bradnock [24] in England, 3 deaths out of 22 in the series by Capelle in France [25], and 8% of deaths in Texas in the series by Eggink [26] over 20 years (1983-2003). In Brazil, Miranda [27] found mortality of 34.3% before 2002 and 24.8% after 2002 in a 25-year study (1989-2003).

This difference is easily explained in view of all the challenges encountered. These were poor monitoring of pregnancies with the absence of an antenatal diagnosis, poor prenatal care with the absence of in utero transfer, poor conditions of transfer after birth, and the unavailability of optimal conditions for

neonatal resuscitation, notably parenteral nutrition and assisted ventilation.

CONCLUSION

The dismal outcome of gastroschisis in our setup can be attributed to various patient related factors, system related factors, and management related factors. Prematurity, late presentation, out-born patients, improper transfer facilities, lack of TPN, lack of central venous facilities, lack of pre-loaded silastic silo, lack of properly trained staff, and lack of proper neonatal ICU are a few of the factors contributing to the dismal outcome.

As in other sub-Saharan African countries, the mortality of gastroschisis is still dramatic in our country. The management of this pathology faces several challenges which unfortunately reveal the low level of the health system. Emphasis should be placed on better monitoring of pregnancies for antenatal diagnosis and planning of neonatal care. Providing hospitals with adequate equipment remains a very important aspect of care.

Acknowledgements: Nil.

Conflict of Interest: None.

Source of Support: Nil

Consent to Publication: Author(s) declared taking informed written consent for the publication of clinical photographs/material (if any used), from the legal guardian of the patient with an understanding that every effort will be made to conceal the identity of the patient, however it cannot be guaranteed.

Author Contributions: Author(s) declared to fulfil authorship criteria as devised by ICMJE and approved the final version.

REFERENCES

1. Ducellier G, Moussy P, Sahmoune L, Bonneau S, Alanio E, Bory J-P. [Laparoschisis: sonographic and obstetrical factors predicting an unfavorable postnatal evolution]. *Gynécologie Obstétrique & Fertilité*. 2016; 44 :461-7. Article in French
2. Ford K, Poenaru D, Moulot O, Tavener K, Bradley S, Bankole R, et al. Gastroschisis: Bellwether for neonatal surgery capacity in low resource settings? *J Pediatr Surg*. 2016; 51:1262-7.
3. Ade-Ajayi N, Manson J, Lever F, Hesse A, Millar A, Emil S, et al. Gastroschisis: A multi-centre comparison of management and outcome. *Afr J Paediatr Surg*. 2012; 9:17.
4. Soares H, Silva A, Rocha G, Pissarra S, Correia-Pinto J, Guimarães H. Gastroschisis: preterm or term delivery? *Clinics*. 2010; 65:139-42.
5. Fillingham A, Rankin J. Prevalence, prenatal diagnosis and survival of gastroschisis: A registry-based study of gastroschisis. *Prenat Diagn*. 2008; 28:1232-7.
6. Tan KB, Tan KH, Chew SK, Yeo GS. Gastroschisis and omphalocele in Singapore: a ten-year series from 1993 to 2002. *Singapore Med J*. 2008; 49:31-6.
7. Oakes MC, Porto M, Chung JH. Advances in prenatal and perinatal diagnosis and management of gastroschisis. *Semin Pediatr Surg*. 2018; 27:289-99.
8. Boutros J, Regier M, Skarsgard ED. Is timing everything? The influence of gestational age, birth weight, route, and intent of delivery on outcome in gastroschisis. *J Pediatr Surg*. 2009; 44:912-7.
9. Overcash RT, DeUgarte DA, Stephenson ML, Gutkin RM, Norton ME, Parmar S, et al. Factors associated with gastroschisis outcomes. *Obstet Gynecol*. 2014; 124:551-7.
10. Mesas Burgos C, Svenningsson A, Vejde JH, Granholm T, Conner P. Outcomes in infants with prenatally diagnosed gastroschisis and planned preterm delivery. *Pediatr Surg Int*. 2015; 31:1047-53.
11. Hadidi A, Subotic U, Goepl M, Waag KL. Early elective cesarean delivery before 36 weeks vs late spontaneous delivery in infants with gastroschisis. *J Pediatr Surg*. 2008; 43:1342-6.
12. Gupta R, Cabacungan ET. Outcome of neonates with gastroschisis at different gestational ages using a national database. *J Pediatr Surg*. 2018; 53:661-5.

13. Haddock C, Skarsgard ED. Understanding gastroschisis and its clinical management: where are we? *Expert Rev Gastroenterol Hepatol*. 2018; 12:405-15.
14. Wright NJ, Sekabira J, Ade-Ajayi N. Care of infants with gastroschisis in low-resource settings. *Semin Pediatr Surg*. 2018; 27:321-6.
15. Ade-Ajayi N, Wright N, Zani A. Epidemiology, management and outcome of gastroschisis in Sub-Saharan Africa: Results of an international survey. *Afr J Paediatr Surg*. 2015;12:1.
16. Ross AR, Eaton S, Zani A, Ade-Ajayi N, Pierro A, Hall NJ. The role of preformed silos in the management of infants with gastroschisis: a systematic review and meta-analysis. *Pediatr Surg Int*. 2015; 31:473-83.
17. Pastor AC, Phillips JD, Fenton SJ, Meyers RL, Lamm AW, Raval MV, et al. Routine use of a SILASTIC spring-loaded silo for infants with gastroschisis: a multicenter randomized controlled trial. *J Pediatr Surg*. 2008; 43:1807-12.
18. Kunz SN, Tieder JS, Whitlock K, Jackson JC, Avansino JR. Primary fascial closure versus staged closure with silo in patients with gastroschisis: A meta-analysis. *J Pediatr Surg*. 2013; 48:845-57.
19. Wright NJ, Langer M, Norman IC, Akhbari M, Wafford QE, Ade-Ajayi N, et al. Improving outcomes for neonates with gastroschisis in low-income and middle-income countries: a systematic review protocol. *BMJ Paediatr*. 2018; 2:e000392.
20. Bösenberg AT. Neonatal anesthesia with limited resources. *Pediatr Anesth*. 2014; 24:98-105.
21. Ameh EA, Chirdan LB. Ruptured exomphalos and gastroschisis: a retrospective analysis of morbidity and mortality in Nigerian children. *Pediatr Surg Int*. 2000; 16:23-5.
22. Wesonga AS, Fitzgerald TN, Kabuye R, Kirunda S, Langer M, Kakembo N, et al. Gastroschisis in Uganda: Opportunities for improved survival. *J Pediatr Surg*. 2016; 51:1772-7.
23. Payne NR, Pfleghaar K, Assel B, Johnson A, Rich RH. Predicting the outcome of newborns with gastroschisis. *J Pediatr Surg*. 2009; 44:918-23.
24. Bradnock TJ, Marven S, Owen A, Johnson P, Kurinczuk JJ, Spark P, et al. Gastroschisis: one year outcomes from national cohort study. *BMJ*. 2011; 343:d6749-d6749.
25. Capelle X, Schaaps JP, Foidart JM. [Antenatal management and postnatal outcome of fetuses with gastroschisis]. *J Gynécologie Obstétrique Biol. Reprod*. 2007; 36:486-95. Article in French
26. Eggink BH, Richardson CJ, Malloy MH, Angel CA. Outcome of gastroschisis: a 20-year case review of infants with gastroschisis born in Galveston, Texas. *J Pediatr Surg*. 2006; 41:1103-8.
27. Miranda ME, Emil S, de Mattos Paixão R, Piçarro C, Cruzeiro PCF, Campos BA, et al. A 25-year study of gastroschisis outcomes in a middle-income country. *J Pediatr Surg*. 2019; 54:1481-6.