

Sex Determination Using Mandibular Ramus Flexure Width On Left Side In South Indian Population - A Short Study

Ashwin Krishna B¹, Dr. Dinesh²

¹Undergraduate, Saveetha Dental College and Hospitals, Saveetha Institute of Medical and Technical Sciences, Saveetha University, Chennai-600077,

Email id - 152001067.sdc@saveetha.com

²Associate Professor, Department of pedodontics, Saveetha Dental College and Hospitals, Saveetha Institute of Medical and Technical Sciences, Saveetha University, Chennai-600077,

Email - dineshkumarb.sdc@saveetha.com

[Cite this paper as:](#) Ashwin Krishna B, Dr. Dinesh (2024) Sex Determination Using Mandibular Ramus Flexure Width On Left Side In South Indian Population - A Short Study..Journal of Neonatal Surgery, 13, 2444-2449

ABSTRACT

Introduction : Sex of an individual can be identified by bones eg with all the bones we can identify the sex by 100%. Mandible is considered as one of the stronger bones of the skull available for gender identification. Mandibular measurements can be used for the identification of gender either on dry mandible or through panoramic radiography or cone-beam computed tomography

Aim: The purpose of our study is to assess the usefulness of mandibular ramus flexure (left) in gender determination.

Materials and methods: An orthopantomograph was used in a retrospective study of 60 subjects (30 males and 30 females). They ranged in age from 20 to 40 years. For the study, ideal orthopantomography was chosen. These samples were separated based on their birth date and the date of the radiograph.

Results: The ramus flexure of males were 2.93 and the ramus flexure of females were 2.67. The standard deviation of males was 0.73968 and females were 0.66089. The difference between males and females was 0.07879. The standard mean error of males was 0.13505 and females was 0.12066. The difference in standard mean error was 0.01439.

Conclusion: We discovered that orthopantomograph measurements of the mandibular ramus flexure (left side) were reliable for determining sex. As a result, we strongly advise using mandibular ramus flexure (left side) as a forensic aid for gender determination...

Keywords: mandibular ramus flexure, sex determination, radiographs.

INTRODUCTION

Sex-determination system is a biological system that determines the development of sexual characteristics in an organism. Sex of an individual can be identified by bones eg with all the bones we can identify the sex by 100%. Mandible is considered as one of the stronger bones of the skull available for gender identification. Mandibular measurements can be used for the identification of gender either on dry mandible or through panoramic radiography or cone-beam computed tomography(1).The pelvis is the most accurate part of the skeleton for sex determination. And there are a number of morphological differences between males and females(2). Here we have a male pelvis. The differences between male and female pelvises are the most accurate way of determining sex in individuals(3).

In the absence of DNA results, skeletal remains can be used to infer the gender of a subject using two methods: morphological and anthropometric(4). The morphological approach is based on examining the bones that exhibit the most sexual dimorphism, primarily the skull and pelvis(5). This method, however, is not always accurate, especially if the skull is fragmented or incomplete. Age can also have an impact on the results, particularly in elderly women whose skull morphology resembles that of men(6). Although morphological methods are critical for a preliminary sex assessment, they also rely on the examiner's experience and are thus somewhat subjective and unreliable(7).

Gender analysis and estimation are performed with nearly 90 to 100% accuracy using a complete skeleton in defining morphologic features for gender determination(8). On the other hand, determining identity can be difficult when incomplete or fragmentary bones and bodies are severely damaged, as in the case of a mass disaster. The skull is the second-best mark for gender identification after the pelvis(9).

However, in cases where a complete dry skull is not found, the mandible, as the largest, most rigid, and dimorphic bone of the skull, may play an important role in gender determination. It is sensitive during the development of children and has many dimorphic characteristics that can be used to estimate gender(10).

Mandibular characteristics, such as the gonial angle, ramus length and breadth, flexure and other morphologic measurements have been reported. Simultaneously, the dependability of these measurements has sparked debate among researchers. The dimorphic characteristics of some parameters used in other jaw studies were inconsistent in the literature. (11) Furthermore, it is well known that skeletal features differ between different populations. As a result, each population necessitates a self-specific criterion for gender assessment. The purpose of our study is to assess the usefulness of mandibular ramus flexure (left) in gender determination.

MATERIALS AND METHODS:

This study was conducted in the department of forensic odontology and the samples were collected from the archives of the department of oral medicine and radiology units, saveetha dental college, chennai. An orthopantomograph was used in a retrospective study of 60 subjects (30 males and 30 females). They ranged in age from 20 to 40 years. For the study, ideal orthopantomographs was chosen. These samples were separated based on their birth date and the date of the radiograph. The study excluded pathological, fractured, deformed, and developmental mandible disturbances. To avoid bias, each radiograph was assigned a code that did not reveal the patient's gender at the time of analysis. These radiographs were then viewed in Planmeca Rome ix viewer software 2.9.2.R. The presence or absence of a distinct flexure or angulation of the posterior margin of the mandibular ramus at the level of the occlusal plane, which appears to be an extremely accurate predictor of sex, was discovered to aid in the determination of sex. A tangent line was drawn on the ramus's posterior margin, and an orientation line was drawn on the occlusal plane of the mandibular molars, which was extended to the ramus. Because the radiographs used in this investigation were already in the system, no ethical approval was required.

For male- Ramus flexure present at the level of occlusion or above the level of occlusion

For female- Ramus flexure sometimes absent (looks straight), if present, maybe above or below the level of occlusion.

1).Upper ramus breadth: the distance between the ramus's most anterior and most posterior points as it passes through the sigmoid notch.

2).Lower ramus breadth: the distance along a line parallel to the previous one from the most anterior to the most posterior point of the ramus at the level of the occlusal plane. (For each side, an average ramus breadth value of upper and lower ramus was calculated and used for further analysis.)

A horizontal orientation line was digitally traced through the summit of the gonial angle for standardisation and was used for the following measurements:

3).Condylar ramus height: The distance from the condylion (the craniometric point at the tip of the mandibular condyle) to the intersection of the orientation line with the inferior border of the ramus.

4).Projective ramus height :The projective distance between the condyloid and the orientation line.

5).Coronoid ramus height: the distance between the coronion (the craniometric point at the tip of the mandibular coronoid process) and the orientation line's intersection with the inferior border of the ramus.

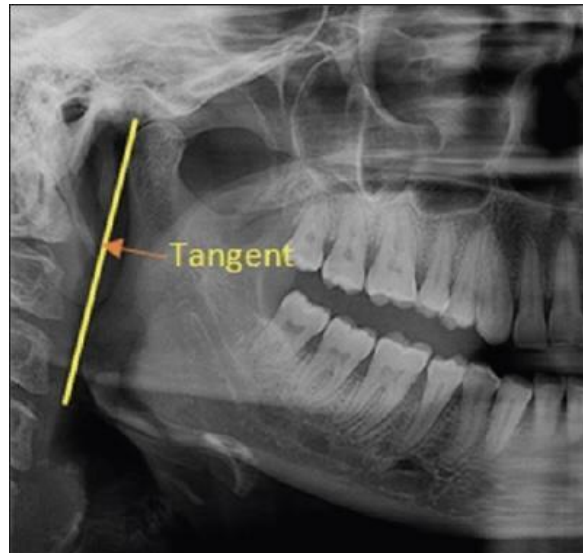


FIGURE 1: shows mandibular ramus flexure (right).

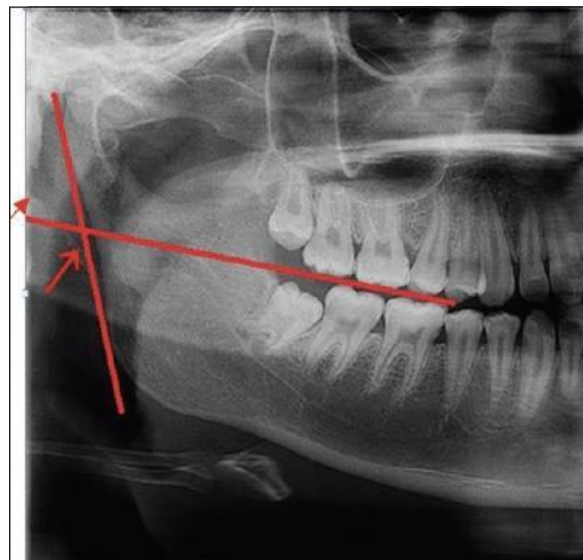


FIGURE 2: shows mandibular ramus flexure (right).

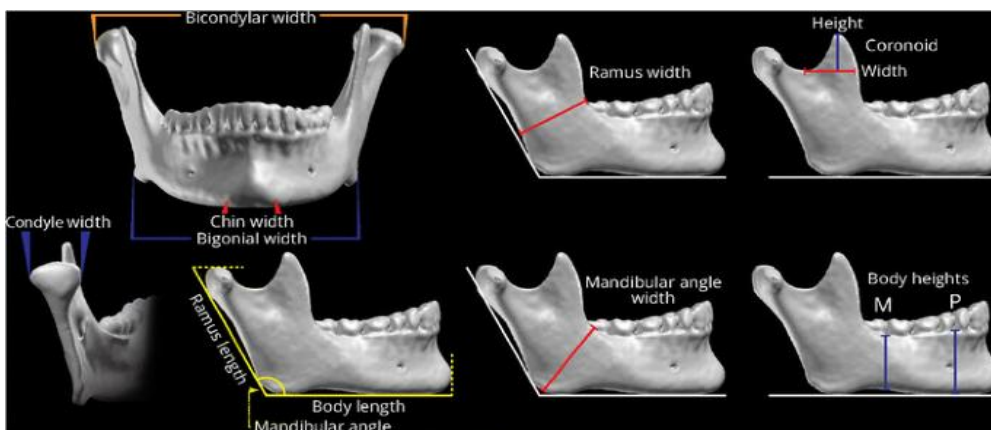
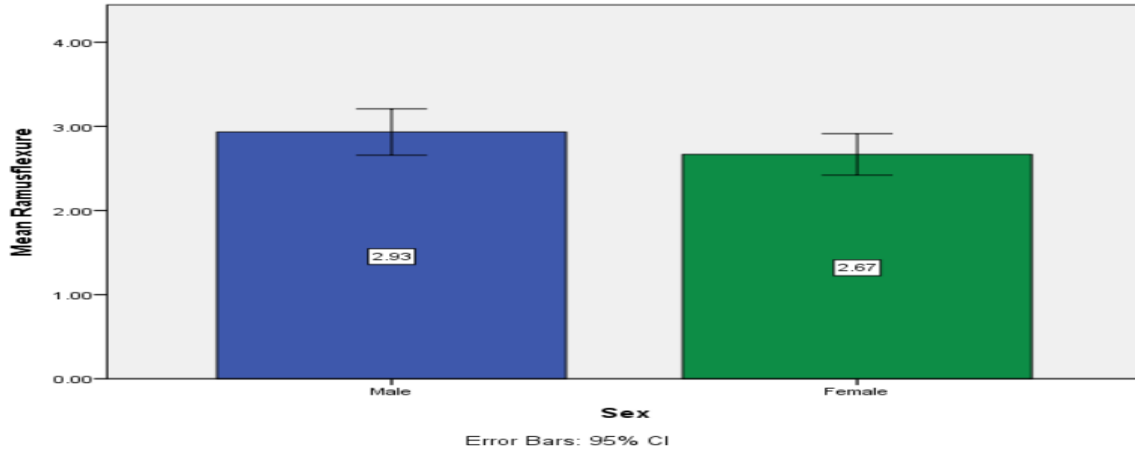


FIGURE 3: shows criteria.

RESULTS:

In this study the ramus flexure of males was higher than the ramus flexure of females. The ramus flexure of males were 2.93 and the ramus flexure of females were 2.67. The standard deviation of males was 0.73968 and females were 0.66089. The difference between males and females was 0.07879. The standard mean error of males was 0.13505 and females was 0.12066. The difference in standard mean error was 0.01439.



GRAPH 1

GROUP STATISTICS

sex	N	MEAN	STD. DEVIATION	STD. MEAN ERROR
Ramusflexure Male	30	2.9333	.73968	.13505
Female	30	2.6667	.66089	.12066

	levene's test for equality of variances	t	df	Sig (2 tailed)	Mean difference	Std. Error difference	95% confidence interval of the difference	Upper
ramus flexure	.068 .796	1.472	58	0.146	0.26667	0.18110	0.09584	0.62918
1).Equal variances assumed								
2). Equal variances not assumed		1.472	57.280	0.146	0.26667	0.18110	0.09594	0.62927

DISCUSSION:

The identification of sex from human remains is critical in forensic medicine and anthropology, particularly in criminal investigations, the identification of missing people, and attempts to reconstruct the lives of ancient populations(12). Determine sex from fragmented jaws and dentition is an important aspect of forensics(13). Sex identification based on morphological marks is subjective and likely to be inaccurate, whereas methods based on measurements and morphometry are accurate and can be used to determine sex from the skull(14). Mandibles were used for the analysis for two simple reasons: first, there appear to be few standards that use this element, and second, this bone is frequently recovered largely intact. In my study it is seen that males have higher mandibular ramus flexure (2.93) than females (2.67).

Panorama radiography has been proven to be accurate in providing anatomic measurements. The orthopantomograph has been advocated as a routine and widely used screening tool for the diagnosis of oral diseases by clinicians(10). The primary benefits of panoramic images are their broad coverage, low patient radiation dose, and quick image acquisition time. Other advantages include the absence of superimposed image interference. Additionally, image enhancement and enlargement provide an accurate and reproducible method of measuring the selected points. The limitations of this technique are magnification and geometric distortion; the vertical dimension is little altered in comparison to the horizontal dimension; and this technique is quite sensitive to positioning errors due to the relatively narrow image layer.

Donnelly et al. (1998)(7), Indrayana et al. (1998), Hill (2000), and Kemkes-Grottenthaler et al. (2002) investigated the sexual dimorphism of the mandibular ramus flexure using direct visual assessment and found that the results were contradictory and not repeatable. Haun (15)(2000) questions the predictive accuracy of mandibular ramus flexure as a single indicator of sexual dimorphism and advises caution when using this technique in the absence of other morphological and osteometric indicators, particularly when dealing with fragmentary forensic or rare fossil remains. (7,16) Giles used anthropometric measurements on mandibles of known sex and reported mandibular ramus height, maximum ramus breadth, and minimum ramus breadth as highly significant, with an accuracy of 85% in American Whites and Negroes(17,18). In South African Whites, Steyn and Iscan (1998) achieved an accuracy of 81.5% with five mandibular parameters (i.e. bigonial breadth, total mandibular length, bicondylar breadth, minimum ramus breadth, and gonion-gnathion). (19)Dayal et al. (2008) discovered that mandibular ramus height was the most accurate parameter in their study, with 75.8% accuracy.(20)

CONCLUSION:

Because of its resistance to damage and disintegration, the mandibular ramus can be considered a valuable tool in gender determination. We discovered that orthopantomograph measurements of the mandibular ramus flexure (left side) were reliable for determining sex. As a result, we strongly advise using mandibular ramus flexure (left side) as a forensic aid for gender determination. Further research on more diverse populations to assess the significance of these parameters is recommended in light of these findings.

ACKNOWLEDGEMENT:

The author would like to thank all the participants for their valuable support and Saveetha Dental College for their support to conduct the study.

FUNDING SOURCE:

The present project was funded by
Saveetha Institute of Medical and Technical Sciences
Saveetha Dental College and Hospital
Saveetha University
Transking medical academy private limited.

CONFLICT OF INTEREST:

All the authors declare that there was no conflict of interest in the present study.

AUTHORS CONTRIBUTION:

ASHWIN KRISHNA: Literature search, data collection, analysis, manuscript drafting .

Abirami arthanari: Data verification, manuscript drafting...

REFERENCES

1. Indira AP, Markande A, David MP. Mandibular ramus: An indicator for sex determination - A digital radiographic study. *J Forensic Dent Sci.* 2012 Jul;4(2):58–62.
2. Saunders SR, Herring A. *Grave Reflections: Portraying the Past Through Cemetery Studies.* Canadian Scholars Press; 1995. 281 p.
3. Schmitt A. *Forensic Anthropology and Medicine: Complementary Sciences From Recovery to Cause of Death.* Springer Science & Business Media; 2007. 480 p.
4. Biswas G. *Recent Advances in Forensic Medicine and Toxicology - 2: Good Practice Guidelines and Current Medicolegal Issues.* JP Medical Ltd; 2018. 692 p.
5. Mann RW, Lozanoff S. *Photographic Regional Atlas of Non-Metric Traits and Anatomical Variants in the Human Skeleton.* Charles C Thomas Publisher; 2016. 744 p.
6. Dolinak D, Matshes E, Lew EO. *Forensic Pathology: Principles and Practice.* Elsevier; 2005. 616 p.
7. Iscan MY, Steyn M. *THE HUMAN SKELETON IN FORENSIC MEDICINE: (3rd Ed.).* Charles C Thomas Publisher; 2013. 516 p.
8. Society of the Sons of the Revolution in the Commonwealth of Massachusetts. *Register of Members of the Society of Sons of the Revolution in the Commonwealth of Massachusetts.* 1895. 170 p.
9. Franklin D, O'Higgins P, Oxnard CE, Dadour I. Discriminant function sexing of the mandible of Indigenous South Africans [Internet]. Vol. 179, *Forensic Science International.* 2008. p. 84.e1–84.e5. Available from: <http://dx.doi.org/10.1016/j.forsciint.2008.03.014>
10. Franklin D, O'Higgins P, Oxnard CE, Dadour I. Determination of Sex in South African Blacks by Discriminant Function Analysis of Mandibular Linear Dimensions: A Preliminary Investigation Using the Zulu Local Population [Internet]. Vol. 2, *Forensic Science, Medicine and Pathology.* 2006. p. 263–8. Available from: <http://dx.doi.org/10.1385/fsmp:2:4:263>
11. Franklin D, Oxnard CE, O'Higgins P, Dadour I. Sexual Dimorphism in the Subadult Mandible: Quantification Using Geometric Morphometrics [Internet]. Vol. 52, *Journal of Forensic Sciences.* 2007. p. 6–10. Available from: <http://dx.doi.org/10.1111/j.1556-4029.2006.00311.x>
12. Dorion RBJ. *Bitemark Evidence: A Color Atlas and Text, 2nd Edition.* CRC Press; 2011. 680 p.
13. Reddy S, Tavares AI. *Evaluation of Health Services.* BoD – Books on Demand; 2020. 130 p.
14. Senn DR, Weems RA. *Manual of Forensic Odontology, Fifth Edition.* CRC Press; 2013. 461 p.
15. Neugebauer EAM, Sauerland S, Fingerhut A, Millat B, Buess GF. *EAES Guidelines for Endoscopic Surgery: Twelve Years Evidence-Based Surgery in Europe.* Springer Science & Business Media; 2007. 414 p.
16. Plemons E. *The Look of a Woman: Facial Feminization Surgery and the Aims of Trans- Medicine.* Duke University Press; 2017. 208 p.
17. Latham KE, Bartelink EJ, Finnegan M. *New Perspectives in Forensic Human Skeletal Identification.* Academic Press; 2017. 374 p.
18. Silver WE, Souviron RR. *Dental Autopsy.* CRC Press; 2009. 276 p.
19. Leiva V. *The Birnbaum-Saunders Distribution.* Academic Press; 2015. 154 p.
20. Hill CA. Technical note: evaluating mandibular ramus flexure as a morphological indicator of sex. *Am J Phys Anthropol.* 2000 Apr;111(4):573–7..