

Impact of Advanced Radiological Imaging on Oxidative Stress, Inflammation, and Recovery in Gynecologic Surgery.

Badar Jahan¹, Saad Qayyum², Shazia Junaid³, Abdul Rahman Abid^{*4}, Kiran Shaikh⁵, Sarah Saad⁶

¹Associate Professor, Department of General Surgery, SMBBMC Lyari, Pakistan.

Email: dr.badarjehan@yahoo.com

²Associate Professor, Department of Radiology, Shalamar Hospital, Lahore, Pakistan.

Email: saadqayyum75@gmail.com

³Assistant Professor, Department of Physiology, Bahria University Health Sciences, Islamabad, Pakistan.

Email: shaziajunaid@yahoo.com

⁴Assistant Professor, Department of Biochemistry, Independent Medical College, Faisalabad, Pakistan.

Email: aliabdulah452@gmail.com

⁵Assistant Professor, Department of Pathology, Isra University Hospital, Hyderabad, Pakistan.

Email: kiran.shaikh@isra.edu.pk

⁶Senior Demonstrator, Department of Physiology, CMH LMC & IOD, Lahore, Pakistan.

Email: drsarahsaad2430@gmail.com

Corresponding Author:

Abdul Rahman Abid.

Email: aliabdulah452@gmail.com

Cite this paper as Badar Jahan, Saad Qayyum, Shazia Junaid, Abdul Rahman Abid, Kiran Shaikh, Sarah Saad. (2025) Impact of Advanced Radiological Imaging on Oxidative Stress, Inflammation, and Recovery in Gynecologic Surgery... Journal of Neonatal Surgery, 14, (33s) 740-744

ABSTRACT

Background: Advanced radiological imaging has significantly improved the diagnosis and surgical planning of gynecologic diseases. Imaging modalities such as magnetic resonance imaging (MRI), computed tomography (CT), ultrasound, and intraoperative imaging technologies are increasingly used to guide minimally invasive gynecologic procedures. These techniques may influence surgical precision, perioperative stress responses, inflammatory processes, and postoperative recovery.

Objective: To evaluate the impact of advanced radiological imaging on oxidative stress, inflammatory responses, and postoperative recovery among patients undergoing gynecologic surgery.

Methods: A prospective observational study was conducted in the Department of Gynecology and Radiology of a tertiary care hospital from January 2024 to December 2024. A total of 120 women undergoing gynecologic surgery were enrolled and divided into two groups: Group A (n=60) underwent surgery planned using advanced radiological imaging techniques (MRI and CT-based planning), while Group B (n=60) underwent conventional imaging-based surgical planning (ultrasound only). Preoperative and postoperative biomarkers including malondialdehyde (MDA), superoxide dismutase (SOD), C-reactive protein (CRP), and interleukin-6 (IL-6) were measured. Postoperative recovery parameters including hospital stay, complication rates, and pain scores were recorded.

Results: Patients in Group A demonstrated significantly lower postoperative oxidative stress markers and inflammatory biomarkers compared with Group B. Mean postoperative CRP levels were significantly reduced in the advanced imaging group (18.3 ± 5.2 mg/L vs 29.6 ± 6.1 mg/L, $p < 0.001$). Similarly, IL-6 levels were lower in Group A (42.5 ± 9.4 pg/ml vs 65.8 ± 10.1 pg/ml, $p < 0.001$). Oxidative stress marker MDA levels were significantly reduced, while antioxidant enzyme SOD levels were higher in the advanced imaging group. Patients receiving advanced imaging planning also experienced shorter hospital stays and faster recovery.

Conclusion: Advanced radiological imaging plays an important role in improving surgical precision, reducing tissue injury,

..

attenuating inflammatory responses, and promoting faster postoperative recovery in gynecologic surgery.

Keywords: Radiological imaging, gynecologic surgery, oxidative stress, inflammation, MRI, CT scan, postoperative recovery

INTRODUCTION

Gynecologic disorders including uterine fibroids, ovarian cysts, endometriosis, and gynecologic malignancies represent a substantial proportion of surgical cases in women worldwide. Surgical intervention remains a cornerstone in management; however, surgical trauma triggers complex physiological responses involving inflammation, oxidative stress, and immune activation, influencing postoperative recovery, complication rates, and long-term outcomes. Optimizing surgical planning and reducing intraoperative tissue injury are major goals in modern gynecologic practice [1].

Radiological imaging plays a critical role in diagnosis, staging, and surgical planning. Ultrasound remains the first-line modality due to accessibility and cost-effectiveness. Advances in MRI, CT, and hybrid imaging significantly improve detection and anatomical mapping, allowing precise surgical strategies and minimizing tissue manipulation [2]. MRI is the gold standard for local staging of many malignancies, CT evaluates metastasis and lymph nodes, and transvaginal ultrasound is useful for initial pelvic evaluation [3]. Integration of these modalities allows accurate determination of lesion size, vascularity, and organ involvement, enhancing surgical precision and outcomes.

Modern imaging also supports minimally invasive surgery. Image-guided procedures facilitate targeted dissection, preserving healthy tissue, reducing operative times, complications, and promoting faster recovery [4]. Surgical trauma activates inflammatory pathways and oxidative stress, with cytokines like IL-6, TNF- α , and CRP contributing to pain, tissue damage, and delayed healing. Excess ROS damages lipids, proteins, and DNA, implicated in conditions like PCOS, endometriosis, infertility, and ovarian aging [5]. Elevated oxidative stress markers (MDA) and reduced antioxidants (SOD) worsen inflammation and tissue repair, contributing to disease progression [6].

Advanced imaging indirectly reduces these responses by improving surgical accuracy and minimizing tissue damage. Emerging technologies such as radiomics, AI-assisted imaging, and hybrid systems further enhance planning and diagnostics [7]. Imaging is also essential in postoperative monitoring, detecting complications like hemorrhage, infection, or recurrence, guiding timely interventions [8]. Despite widespread use, limited studies assess imaging's influence on inflammation and oxidative stress. This study aims to evaluate the impact of advanced radiological imaging on oxidative stress, inflammatory responses, and postoperative recovery among patients undergoing gynecologic surgery.

Methods

A prospective observational study was conducted at a tertiary care hospital between January 2024 and December 2024. The study included 120 women who were scheduled for elective gynecologic surgery during the study period. Eligible participants were women aged between 20 and 60 years who were undergoing surgery for either benign or malignant gynecologic conditions or who provided informed consent to participate in the study. Patients with systemic inflammatory diseases, chronic liver or kidney disorders, or those receiving antioxidant therapy were excluded in order to avoid potential confounding factors that could influence inflammatory and oxidative stress markers.

The enrolled participants were divided into two groups based on the type of preoperative imaging used for surgical planning. Group A consisted of patients whose surgeries were planned using advanced radiological imaging techniques such as magnetic resonance imaging (MRI) and computed tomography (CT). Group B included patients whose surgical planning was based on conventional imaging using ultrasound alone.

For biochemical assessment, venous blood samples were collected from all participants prior to surgery and again 24 hours after the surgical procedure. The collected samples were analyzed for markers related to oxidative stress and inflammation. Malondialdehyde (MDA) was measured as a marker of oxidative stress, while superoxide dismutase (SOD) was evaluated as an indicator of antioxidant defense. Inflammatory response was assessed by measuring C-reactive protein (CRP) and interleukin-6 (IL-6) levels.

In addition to biochemical parameters, several clinical recovery indicators were also evaluated. These included the duration of surgery, postoperative pain score using the Visual Analog Scale (VAS), length of hospital stay, and the occurrence of postoperative complications. These parameters were used to assess the overall recovery and clinical outcomes following surgery.

Statistical analysis of the collected data was performed using SPSS version 26. Quantitative variables were expressed as mean \pm standard deviation. Comparisons between the two groups were carried out using the independent t-test for continuous variables and the chi-square test for categorical variables. A p-value of less than 0.05 was considered statistically significant.

Results

The baseline characteristics of the patients were generally similar between the two groups, indicating that the study population was well-matched for factors such as age and BMI (Table 1). Despite this similarity, the use of advanced imaging in Group A was associated with a notably shorter duration of surgery compared with conventional imaging, suggesting that preoperative planning with advanced modalities may facilitate more efficient and precise surgical procedures.

Postoperative trends further highlight the benefits of advanced imaging. Patients in Group A showed lower inflammatory and oxidative stress markers, reflecting a reduced systemic response to surgical trauma (Tables 2 and 3). This attenuation of inflammation and oxidative stress corresponded with improved recovery outcomes, including shorter hospital stays and fewer complications (Table 4). Overall, these trends suggest that integrating advanced imaging into preoperative planning can not only optimize surgical efficiency but also enhance postoperative recovery and reduce adverse events.

Table 1: Baseline Characteristics of Patients

Variable	Group A (Advanced Imaging)	Group B (Conventional Imaging)	p-value
Age (years)	42.1 ± 8.6	41.5 ± 7.9	0.62
BMI (kg/m ²)	26.3 ± 3.1	25.8 ± 3.4	0.48
Duration of surgery (min)	95 ± 18	118 ± 22	<0.001

Table 2: Postoperative Inflammatory Markers

Parameter	Group A	Group B	p-value
CRP (mg/L)	18.3 ± 5.2	29.6 ± 6.1	<0.001
IL-6 (pg/ml)	42.5 ± 9.4	65.8 ± 10.1	<0.001

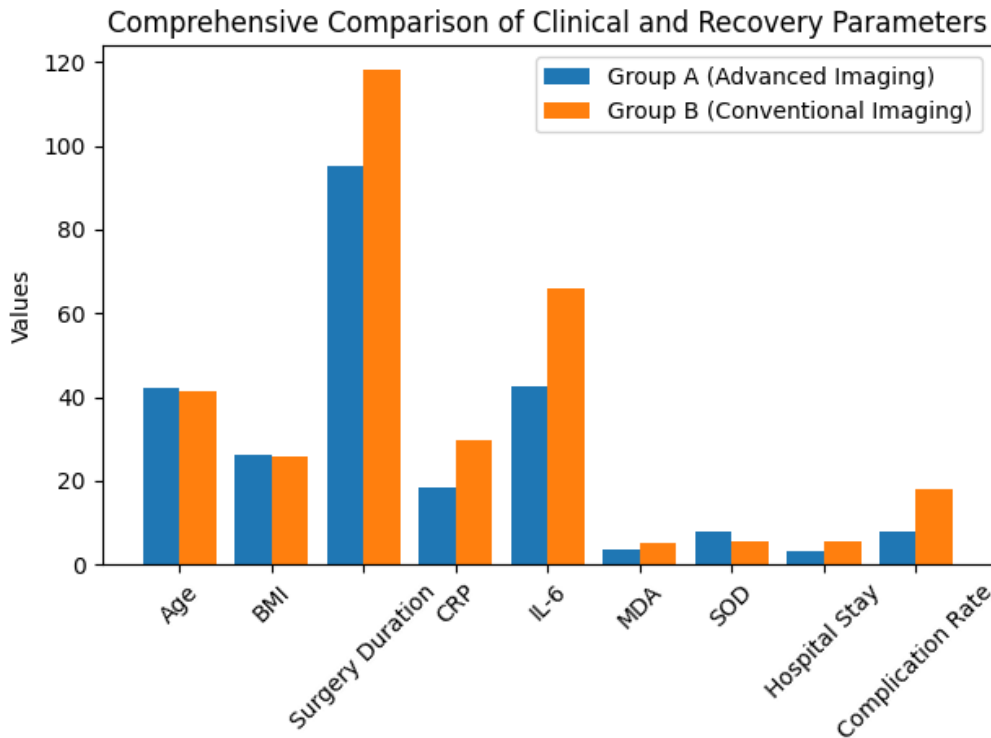
Table 3: Oxidative Stress Markers

Parameter	Group A	Group B	p-value
MDA (nmol/ml)	3.4 ± 0.9	5.1 ± 1.2	<0.001
SOD (U/ml)	7.8 ± 1.4	5.6 ± 1.3	<0.001

Table 4: Recovery Outcomes

Parameter	Group A	Group B	p-value
Hospital stay (days)	3.2 ± 0.8	5.4 ± 1.2	<0.001
Complication rate	8%	18%	0.04

Patients undergoing surgery with advanced imaging guidance experienced significantly improved recovery outcomes compared to those undergoing conventional imaging-based surgery.



DISCUSSION

The present study demonstrates that advanced radiological imaging in gynecologic surgery is associated with reduced postoperative inflammatory responses, lower oxidative stress, and improved recovery outcomes. Patients planned with MRI and CT showed significantly lower levels of CRP and IL-6 compared with those undergoing conventional imaging-based surgery, highlighting the role of imaging in enhancing surgical precision and reducing physiological stress.

Advanced imaging is essential in modern gynecologic practice, enabling accurate visualization of pelvic structures and disease extent [1]. MRI, in particular, allows precise evaluation of soft tissue and tumor spread in cervical cancer, endometrial carcinoma, and ovarian malignancies, improving preoperative planning and operative technique selection [9]. Reduced inflammatory markers in this study may reflect more targeted surgical approaches, as excessive tissue manipulation triggers cytokine cascades, particularly IL-6, which is linked to postoperative complications and delayed recovery [10].

Oxidative stress contributes to postoperative tissue injury via reactive oxygen species that damage cellular membranes, mitochondria, and DNA. Imaging-guided planning was associated with lower malondialdehyde (MDA) levels and higher superoxide dismutase (SOD) activity, suggesting reduced oxidative stress [11]. Prior research confirms oxidative stress is integral to endometriosis, polycystic ovarian syndrome, and infertility, affecting serum, follicular fluid, and endometrial tissues [10,11].

Imaging also supports minimally invasive surgery, including laparoscopic and robotic approaches, which reduce incision size, tissue manipulation, postoperative pain, hospital stay and recovery time. Imaging enhances these techniques by providing detailed preoperative anatomy [12]. Postoperative evaluation benefits from imaging modalities such as CT and MRI, which detect complications like abscess, hemorrhage, and tumor recurrence, facilitating early intervention [13]. Advances including artificial intelligence, radiomics, and machine learning further improve diagnostic accuracy and prediction of surgical outcomes [14,15]. The observed shorter hospital stay and lower complication rate reinforce evidence from previous studies that preoperative imaging promotes enhanced recovery by minimizing trauma, controlling inflammation, and optimizing care [16, 17].

CONCLUSION

Advanced radiological imaging significantly improves surgical precision and postoperative recovery in gynecologic surgery. The use of imaging technologies such as MRI and CT scans reduces oxidative stress, decreases inflammatory responses, shortens hospital stay, and lowers complication rates. Incorporating advanced imaging into routine surgical planning may enhance patient outcomes and contribute to more effective management of gynecologic diseases.

Disclaimer: None

Conflict of Interest: None

Funding: None

Authors' Contribution:

Concept & Design of Study: Badar Jehan, Abdul Rahman Abid , Saad Qayyum, Sarah Saad

Drafting: Abdul Rahman Abid, Shazia Junaid, Kiran Shaikh

Data Analysis: , Sarah Saad, Kiran Shaikh , Shazia Junaid

Critical Review: Badar Jehan, Abdul Rahman Abid

Final Approval of Version: All authors approved the final version

REFERENCES

1. KD, Fuchs HE, Jemal A. Cancer statistics, 2024. *CA Cancer J Clin.* 2024;74(1):17-48.
2. Timmerman D, Bourne T. Ultrasound in gynecologic imaging: current and future perspectives. *Ultrasound Obstet Gynecol.* 2022;60(2):153-160.
3. Daoud T, Sardana S, Stanietzky N, et al. Recent imaging updates and advances in gynecologic malignancies. *Cancers (Basel).* 2022;14(22):5528.
4. Bhosale P, Iyer R. Diagnostic imaging in gynecologic oncology: current practice and future directions. *Radiographics.* 2021;41(4):1170-1190.
5. Papalou O, Victor VM, Diamanti-Kandarakis E. Oxidative stress in gynecological disorders. *Redox Biol.* 2021;45:102037.
6. Uyanikoglu H, Dagli AF, Ozturk A, et al. Oxidative stress biomarkers in gynecologic diseases: clinical implications. *Medicine (Baltimore).* 2024;103(16):e37522.
7. Gillies RJ, Kinahan PE, Hricak H. Radiomics: images are more than pictures, they are data. *Nat Rev Cancer.* 2022;22(8):434-446.
8. Moradi B, Hejazian SS, Tahamtan M, et al. Imaging the post-treatment pelvis in gynecologic cancers: current concepts and future directions. *Abdom Radiol.* 2024;49:1613-1628.
9. Desborough JP. The stress response to trauma and surgery. *Br J Anaesth.* 2022;129(1):33-41.
10. Nezhat C, Li A, Abed S, et al. Laparoscopic surgery in gynecology: advances and current perspectives. *JLS.* 2021;25(4):e2021.00080.
11. Nelson G, Kalogera E, Dowdy SC. Enhanced recovery pathways in gynecologic surgery. *Gynecol Oncol.* 2022;167(1):1-9.
12. Thomassin-Naggara I, Daraï E, Cuenod CA, et al. MRI in gynecologic cancers: advances and clinical applications. *Lancet Oncol.* 2021;22(8):e345-e356.
13. Bhatla N, Aoki D, Sharma DN, Sankaranarayanan R. Advances in cervical cancer imaging and staging. *Int J Gynecol Cancer.* 2022;32(4):530-539.
14. Rizzo S, Del Grande F, Colombi D, et al. Imaging and surgical planning in ovarian cancer: current evidence and future perspectives. *Cancer Imaging.* 2023;23(1):38.
15. Sala E, Rockall AG, Freeman SJ, Mitchell DG. MRI of female pelvic malignancies: current clinical applications. *Radiology.* 2021;299(3):543-559.
16. Kuhl CK. Radiology in precision medicine: challenges and opportunities. *Radiology.* 2022;303(3):546-558.
17. Lambin P, Leijenaar RTH, Deist TM, et al. Radiomics and imaging biomarkers in oncology. *Nat Rev Clin Oncol.* 2021;18(12):749-762.
18. Bhosale P, Javitt MC, Atri M, et al. CT and MRI applications in gynecologic malignancies. *AJR Am J Roentgenol.* 2023;221(3):509-521.